

RECURRENT ANAPLASTIC MENINGIOMA AFTER SURGERY AND RADIATION THERAPY FOR BASAL CELL CARCINOMA - CASE REPORT

A. Kaprelyan, N. Deleva

Neurology department,

Prof. Paraskev Stoyanov Medical University of Varna, Bulgaria

ABSTRACT

A case-report of 63-year female who developed meningioma after surgery and contact cranial radiotherapy for basal cell carcinoma (BCC) was presented. Initial symptoms appeared in a latency period of 14 years and included moderate frontal and occipital headache, nausea, speech disorder, gait instability, memory impairment and secondary generalized seizure. The tumor lesion visualized on the computed tomography (CT) and the medical history of previous cancer disease led initially our thinking to the diagnosis of cerebral metastasis. Histological verification confirmed anaplastic meningioma. Long-term follow-up of clinical, CT and electrophysiological findings corresponded with the recurrent course of the disease 10 months after gross-total tumor extirpation. Stable course of the disease was established since second operation until now.

Review of the literature concerning incidence and differential diagnosis of post-radiation brain tumors was done. The prior cranial irradiation as a possible risk factor for meningioma development was discussed.

Key words: basal cell carcinoma, radiation therapy, recurrent meningioma, differential diagnosis

INTRODUCTION

Current epidemiological data suggest that brain tumors development could be associated with genetic predisposition or different environmental factors such as radiation, viral infections, head trauma and exposure to various chemical carcinogens (2, 4, 6, 12). Nevertheless the cause of primary brain neoplasms is still unknown the prior cranial irradiation is the most well established risk factor for brain tumors (2, 7, 9). The ionizing radiation given in therapeutic doses in patients with skin cancer as well as radiotherapy of solid tumors and leukemia are supposed to increase the risk of brain gliomas, meningiomas and sarcomas (1, 3, 8, 9, 10, 11, 14).

CASE - REPORT

We report a female who at the age of fifty was admitted to Neurology department of Varna University hospital suffering from moderate frontal and occipital headache, gait instability, nausea, speech disturbance, memory

impairment, left limbs weakness and generalized seizure (3 in last two years). Neurological examination showed left facial palsy, slight pyramidal signs in left limbs, left superficial sensory loss and left hemianopsia. Medical history and documentation confirmed that the patient, at the age of 36 received after surgery a contact cranial radiotherapy (8000 R) for BCC on her nose. Electroencephalography (EEG) demonstrated pathological focus of abnormal activity in right temporal region. Mini Mental State Examination was 27 points. The CT-scan of the brain showed a large hyperdense mass in right occipital region with surrounding edema (fig. 1). A diagnosis of cerebral metastasis was made. The results of chest, abdominal and pelvic bones X-rays and abdominal ultrasound were normal, except data for miomatous uterus. Regardless the intravenous corticosteroid administration the symptoms of raising intracranial hypertension developed and a gross total extirpation of the occipital tumor was performed urgently. Histological verification confirmed anaplastic meningioma. Next months the patient remained well and post-operative CT and EEG demonstrated no tumor development (fig. 2). One year later a large (4x4 cm) contrast enhancing tumor in the right parieto-occipital region was visualized on the control brain CT (fig. 3). Total extirpation of the recurrent tumor mass was performed again. The clinical, radiological and electrophysiological follow-up after second operation corresponded with the stable course of the disease until now.

DISCUSSION

Intracranial meningiomas are one of the most common primary tumors of the brain (2, 5). Genetic and different physical, chemical and biological environmental factors are supposed to play role in their development (2, 4, 5, 6, 7, 12). Apart from genetic predisposition ionizing radiation is considered to be the only well-established risk factor for brain neoplasms.

Review of literature provides evidences that patients, who have undergone cranial irradiation for skin disorders or radiotherapy for cancer and leukemia show high risk for cerebral astrocytomas, meningiomas and sarcomas (1, 3, 8, 9, 10, 11, 14). Reports of survivors of the atomic bomb in Hiroshima who have proportional to their level of ex-

posure increased risk of meningiomas support this possible link (13). Current studies also discuss the involvement of radiofrequency signals or extremely low frequency magnetic fields in malignant cell transformation (5, 7, 12).

Base on these data our case report presents an interest as an example of brain meningioma developed 14 years after contact cranial irradiation for nasal skin cancer. Although the cause of the brain tumor remains unclear the prior contact radiotherapy in therapeutic dose 8000 R may contribute to its appearance. The medical history of previous cancer disease and CT findings led initially our thinking to the diagnosis of cerebral metastasis. Although the histological results confirmed malignant meningioma the description of our case focuses attention on the differential diagnosis with other histological types of radiation-induced brain tumors. Astrocytomas, sarcomas, primary lymphoma or meningioma associated with neurofibromatosis type 2 need to be discussed.

Reports of radiation-induced brain tumors as a late-on complication in patients with leukemia or skin cancer need to be cautiously interpreted, although prior cranial irradiation is the only well-established risk factor for intracranial neoplasms. In our case meningioma originated in previously irradiated area and a latency period of 14 years in accordance with the findings of previous reports (3, 8, 9, 11). This fact demonstrates a possible causative relation between ionizing radiation and tumor development.

We suggest that our case of a recurrent anaplastic meningioma after cranial irradiation for BCC provokes an important diagnostic challenge as the development of neoplasms subsequent to therapeutic cranial irradiation is a rare but serious and sometimes potentially fatal complication. Further experimental and epidemiological research into genetic and environmental risk factors may throw additional light on understanding etiology and pathogenesis of brain tumors.

EEG and CT-scan follow-up of 63-year female (N.K.P.) with radiation-induced recurrent anaplastic meningioma.

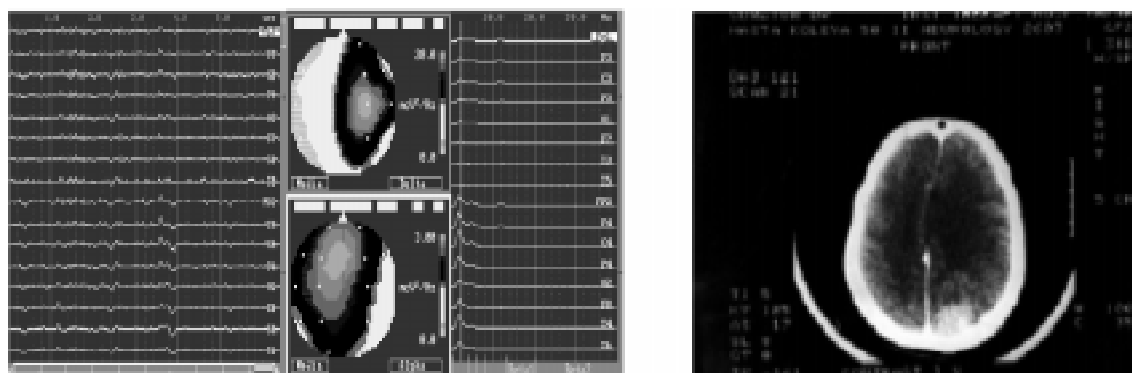


Fig. 1. Initial EEG and CT-scan (hyperdense tumor mass in right occipital region).

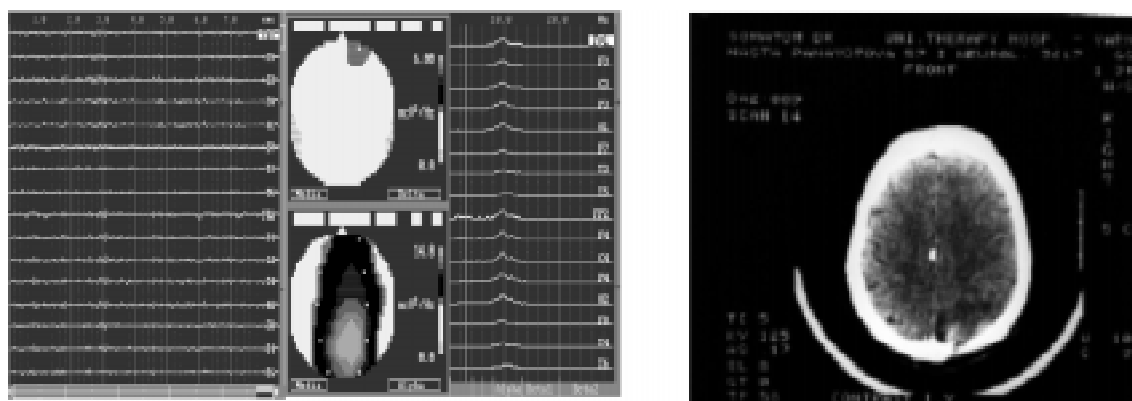


Fig. 2. EEG and CT-scan (postoperative cyst in right occipital region) 2 months after operation.

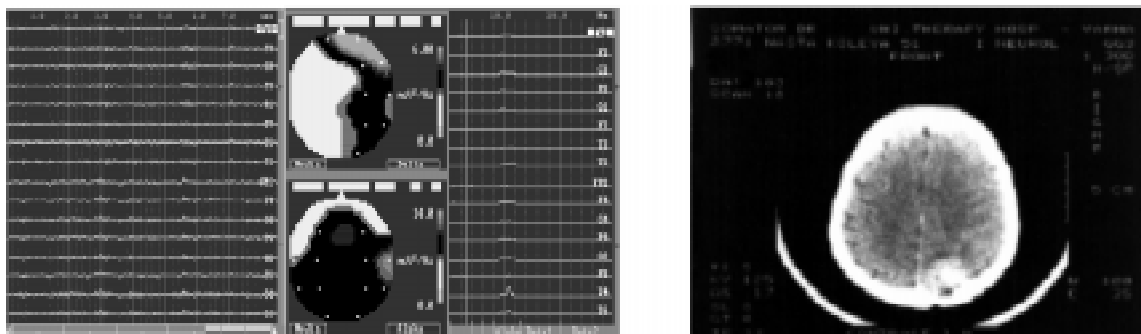


Fig. 3. EEG and CT-scan (recurrent tumor mass in right occipital region) 10 months later.

REFERENCES

1. Топалов Н., Танева Н., Ганева Г. Случай на радиационно-индуцирани менингиоми, последвали остра лимфобластна левкемия. *Цефалгия*, 5, 2003, 1, 37-39
2. Adams R., Maurice V. Intracranial neoplasms. In: *Principles of Neurology*, 5th ed., Eds. R. Adams, V. Maurice, McGraw-Hill, 1993, 554-597.
3. Al-Mefty O., Topsaka C.I., Pravdenkova S., Sawyer J. et. al. Radiation-induced meningiomas: clinical, pathological, cytokinetic, and cytogenetic characteristics. *J. Neurosurg.*, 100, 2004, 1002-1013.
4. Borrás J., Yava-Tur R., Sabater S., Pinol J., Servitja S., Guma J., Galceran J. Descriptive epidemiology of central nervous system cancers in Tarragona (Catalonia, Spain). *Neuro-Oncology*, 4, Suppl.1, 2002, S11.
5. De Angelis L., Loeffler J., Mamelak A. Primary brain tumors. Metastatic brain tumors. In: *Cancer management: A multidisciplinary approach*. 8 ed., Eds. R. Pazdur, L. Coia, W. Hoskins, L. Wagman, CMP, 2004, 591-614.
6. Moorthy R., Rajshekhar V. Development of glioblastoma multiforme following traumatic cerebral contusion: case report and review of literature. *Surg. Neurol.*, 61, 2004, 180-184.
7. McKinney P. Brain tumours: incidence, survival, and aetiology. *J. Neurol. Neurosurg. Psychiatry*, 75, 2004, Suppl. 2, 12-17.
8. Nishio S., Morioka T., Inamura T., Takeshita I., Fukui M., Sasaki M., Nakamura K., Wakisaka S. Radiation-induced brain tumours: potential late complications of radiation therapy for brain tumours. *Acta Neurochir (Wien)*, 140, 1998, 8, 763-70.
9. Sadetzki S, Chetrit A, Freedman L, Stovall M, Modan B, Novikov I. Long-term follow-up for brain tumor development after childhood exposure to ionizing radiation for tinea capitis. *Radiat. Res.*, 164, 2005, 2, 234.
10. Salvati M, Frati A, Russo N, Caroli E, Polli F, Minniti G, Delfini R. Radiation-induced gliomas: report of 10 cases and review of the literature. *Surg. Neurol.*, 60, 2003, 1, 60-67.
11. Salvati M., Cervoni L., Puzzialli F., Bristot R., Delfini R., Gagliardi F. High dose radiation-induced meningiomas. *Surg. Neurol.*, 47, 1997, 5, 435-441.
12. Tongzhang Z., Cantor K., Zhang Y., Keim S., Lynch Ch. Occupational Risk Factors for Brain Cancer: A Population-Based Case-Control Study in Iowa. *Journal of Occupational and Environmental Medicine*, 43, 2001, 4.
13. Yonehara S, Brenner A, Kishikawa M, Inskip P, Preston D, Ron E, Mabuchi K, Tokuoka S. Clinical and epidemiologic characteristics of first primary tumors of the central nervous system and related organs among atomic bomb survivors in Hiroshima and Nagasaki, 1958-1995. *Cancer*, 101, 2004, 7, 1644-1654.
14. Watanabe T, Fuse T, Umezu M, Yamamoto M, Demura K, Niwa Y. Radiation-induced osteosarcoma 16 years after surgery and radiation for glioma - case report. *Neurol Med Chir (Tokyo)*, 46, 2006, 1, 51-54.

Address for correspondence:

Dr. Ara Kaprelyan, PhD
 Department of Neurology,
 Prof. Paraskev Stoyanov Medical University of Varna,
 55 Marin Drinov Street, BG-9002 Varna, Bulgaria
 e-mail: arakapri07@yahoo.co.uk