

SELECTIVE PRESSURE IMPRESSIONS METHODS FOR TOTAL DENTURES BY PATIENTS WITH LOOSE AND HYPERMOBILE MUCOSA ON THE ALVEOLAR RIDGES

Hzridana Hadjieva, Mariana Dimova
Dept. of Prosthodontics, Faculty of Stomatology,
Medical University-Sofia, Bulgaria

ABSTRACT

Introduction. The mucosa over the alveolar ridges by totally edentulous patients is with varying thickness and mobility at different places and is distorted at the time of impression procedure. This distortion duplicated in the finished dentures causes inflammation and instability of the dentures.

The **aim** of the authors is to present three methods for selective pressure impressions for total dentures' treatment by patients who had different kind of localization and abnormalities of the thickness and mobility of the alveolar ridges' mucosa.

Materials and methods .15 edentulous patients, 9 women and 6 men, mean age 64 years, with different kind of mucosal abnormalities were divided into three groups and treated with full dentures. Three different impression techniques are used for selective pressure impressions.

Results. The silicone pressure tests at the delivery appointment showed even layer of the material over the base plate of the dentures, except for two patients from the first group. with The patients mention for comfort and satisfaction during the usage of the new dentures, compared with the previous one.

Discussion. The secondary impression causes some displacement no matter how carefully is made. The suggested three methods eliminates the excessive displacement of the soft tissues at the secondary impression thus a physiologic and anatomic registration of the attached and the unattached tissue of the denture bearing areas are attained.

Key words: total dentures treatment, hypermobile tissues, impression techniques

INTRODUCTION

The mucosa over the alveolar ridges by totally edentulous patients is with different thickness and mobility. In some regions it is thick from 2-4 mm and the vertical pressure causes distortion of the mucosa, which rebounds after the pressure is eliminated. In other places where the atrophy of the procesus alveolaris was quick and advanced, the mucosa has no bone support and becomes loose and flabby.

Such mucosa is more than 4 mm thick and forms folds usually at the frontal part of the ridges and floating tubers maxillae /1,2,3,6/.

The impression making in total denture treatment is of great importance, not only for denture retention and stability but also for the mucosa status which should be kept and reflected without any distortions./ 4,5 /

The **aim** of the authors is to present three methods for selective pressure impressions for total dentures' treatment by patients who had different kind of localization and abnormalities of the thickness of alveolar ridges' mucosa.

MATERIALS AND METHODS

15 edentulous patients, 9 women and 6 men, mean age 64 years, with different kind of mucosal abnormalities were treated. From them 8 patients, 4 women and 4 man, had flabby mucosa on different places of the alveolar ridges of the both jaws (the first group), 3 women had mucosal folds in the frontal area of the both jaws and 1 man of the upper jaw only (the second group) and 3 patients, two women and one man, had floating tubera maxillae (the third group) Fig. 1.

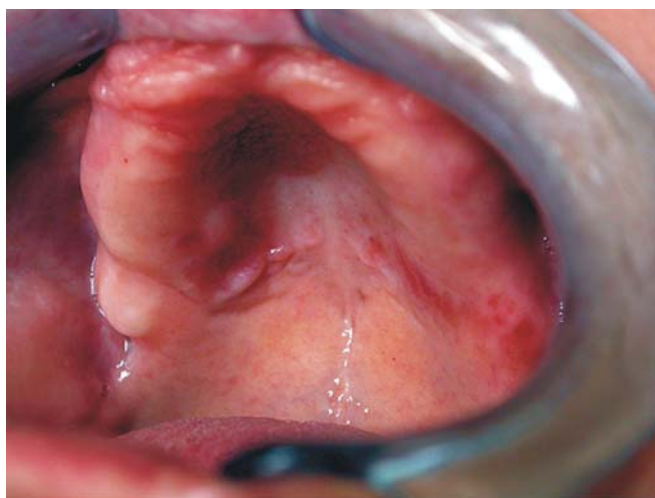


Fig. 1. Flabby and hypermobile mucosa at the front part of the alveolar ridge

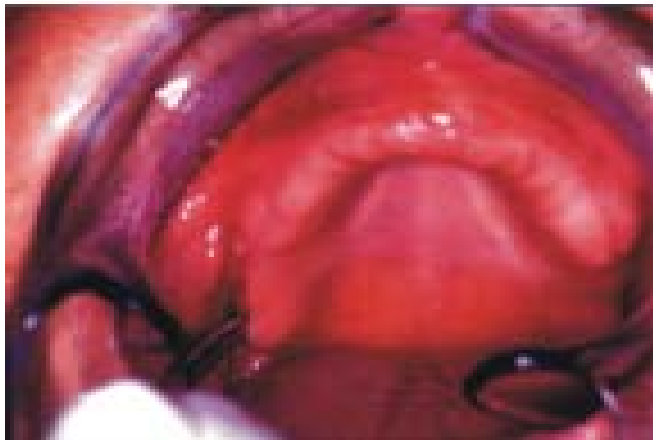


Fig. 2. Floating tuber maxillae

By the first group of patients we used the following method. On the first model the places with flabby mucosa were delineated and as well the places on the "linea raphe mediana" and "torus palatinus". Those spots were then covered with a wax layer 1mm in thickness. After that an individual tray out of shell lack base plate material are formed and holes are drilled at the places corresponding to the critical spots mentioned earlier with a bur N14 approximately 5mm apart.

By patients with hypermobile mucosa at the front part, the so called "pendulous tissues" of the alveolar ridges, we used a method, including an individual tray out of auto polymerizing acrylic resin Duracrol, Spofa Dental in which the anterior part is removed like a "window" corresponding to the place of the mucosal folds. The handle than is prepared in the form of platforms at the distal parts of the tray. This method is described in details in previous publication of ours /8/.

By patients with floating tubera maxillae light-curing polymer base plate were used after the following preparations. On the first model the tubera maxillae and the torus palatinus were delineated and relieved with a layer of wax 1mm in thickness. Another base plate wax covered the whole basal seat i.e. the surface outlined for the tray. Wax is cut away in locations where stops are desired. The tray is completed with the wax spacer as relief. The handle was in form of platforms placed bilaterally, not reaching the tubera. Holes are drilled at the places corresponding to the tubera maxillae and torus palatinus with a bur N14 approx-

imately 3-4 mm apart.

All the impressions were taken after a precise adjustment of the individual tray for stability, retention and muscle interferences.

The impression itself included two phases. By the first step we form and impress the peripheral seal/physiologic borders/ with high viscosity silicone impression material (Xantopren function, Heraeus Kulzer, GmbH&Co.K.G.). After that we put low viscosity "C" silicone impression material (Xantopren M, Heraeus Kulzer, GmbH&Co.K.G.) as a wash impression with moderate pressure. By the second group the silicone material is put by syringe at the place of the "window". The prostheses were processed and at the first appointment a silicone pressure test with Stomaflex-crème, Spofa Dental was made at the delivery appointment. Control appointments were arranged at the 2nd, 7th, 14th day and after a month.

RESULTS

The silicone pressure tests at the delivery appointment showed even layer of the material over the base plate of the dentures, except for two patients from the first group where there were places of excessive pressure spot and the acrylic was seen under the silicone layer. The regions were marked on the dentures and the corresponding parts were corrected with an appropriate stone. On the subsequent appointments the mucosal state of the denture bearing areas was carefully observed and palpated for inflammatory signs but there weren't any. The patients mention for comfort and satisfaction during the usage of the new dentures, compared with the previous one.

DISCUSSION

The secondary impression causes some displacement no matter how carefully is made. Such tissue distortion can result in irritation and dislodgement if duplicated in the finished complete denture. The effects of tissue displacement and distortion during impression making should be eliminated. The use of holes, windows and wax relieve reduces the hydraulic pressure and minimize the displacement of the bearing tissues. The suggested three methods eliminates the excessive displacement of the soft tissues at the secondary impression thus a physiologic and anatomic registration of the attached and the unattached tissue of the denture bearing areas are attained.

REFERENCES:

1. Ralev, R., T. Peev, A. Filtchev: Propeutics of Prosthodontics, Medicina I fizkultura, 1995
2. Akbay, T & Akbay, C. Ultrastructural investigation of hard palate mucosa under complete dentures. J. Prosthet. Dent. 1988, 59, 1, 53-58
3. Boucher C. O., Hickey J. C., Zarb G.A. Prosthodontic treatment of edentulous patients, ed7, St Louis 1975. The CV Mosby, pp133-158
4. Hyde T. P., Mc Cord J. F. Survey of prosthodontic impression procedures for complete dentures in general dental practice in the UK. J. Prosthet. Dent. 1999, Mar. 81(3) 295-9
5. Klein I. E., Broner A. S. Complete denture secondary impressions technique to

minimize distortion of ridge and border tissues. *J. Prosthet. Dent.* 1985, 54, 660-66

6. Sharry J. H. Complete denture prosthodontics ed.3, New York, 1974, MacGraw - Hill Book Co, pp191-211

7. Watson IB, MacDonald DG. Oral mucosa and complete dentures. *J. Prosthet. Dent.* 1982, 47, 1, 133-40

8. Hadjieva, H., M. Dimova: A selective impression method for edentulous pa-

tients with hypermobile and flabby mucosa., Scientific Researches of the Union of Scientists in Bulgaria - Plovdiv, Series D. Medicine, Pharmacy and Stomatology, vol. VI, 2005, 295-300

Address for correspondence:

Dr. Hrizdana Hadjieva,

Dept. of Prosthodontics, Faculty of Stomatology, Sofia,

tel. +359/888 684 291, +359/29549209, e-mail: hrishadj@abv.bg

Journal of IMAB - Annual Proceeding (Scientific Papers) 2005, book 2

TOTAL REHABILITATION BY EDENTULOUS PATIENTS WITH IRREGULARITY OF THE ALVEOLAR RIDGES

Hrizdana Hadjieva Mariana Dimova
*Department of Prosthodontics, Faculty of Stomatology,
Medical University - Sofia, Bulgaria*

ABSTRACT

Introduction. The treatment of edentulous patients is always a challenge for the prosthodontists. It is connected with a lot of procedures aiming to reconstruct and replace the lost natural dentition and associated structures of the mandible and maxilla for patients who have lost all their remaining teeth. The basic objectives of complete denture Prosthodontics are the restoration of function, facial appearance and the maintenance of patient's health.

The **aim** of this work is the prosthetic treatment of patients with asymmetry of alveolar ridges, the difficulties connected with that treatment and the suitable techniques and approaches to overcome those problems.

Material and methods. Twenty patients, twelve women and eight men, with an average age of 64 ± 7 years were included in this investigation. All of them had different type and degree of irregularity of the alveolar ridges. The complaints of the patients were mainly connected with poor denture stability during mastication and with the esthetics. The treatment strategy of those patients included excellent impression of the peripheral seal, very careful measurement of the parameters of the vertical and horizontal occlusal plane, lingualized occlusion and esthetics improvement procedures.

Results: All the twenty patients accepted the new dentures with comfort and esthetical satisfaction and assessed them to be significantly more satisfying in esthetic

appearance, maxillary and mandibular denture retention and chewing ability. To six of them preliminary contacts were eliminated at the delivery appointment. On the second appointment by 3 patients from the third group and one from the first group decubital ulcers were treated.

Conclusion. As complete dentures are the last consideration for the patient (excluding implant treatment) they must be designed and constructed with an emphasis on the preservation of the remaining structures.

Key words: denture retention, denture esthetics, irregularity of the ridges, edentulousness

INTRODUCTION.

One of the most important factors for the successful result of the prosthetic treatment of fully edentulous patients is the stability of the dentures. Factors, influencing the denture base stability are: the kind and the mobility of the oral mucosa; the kind, stage and asymmetry of the jaws' bone resorption; adhesion of the denture base to the denture bearing tissues; the accurate impression of the border (peripheral) tissues; the shape and the inclination of the slopes of the alveolar ridges and the inter-alveolar angle./1/

The **aim** of this work is the prosthetic treatment of patients with asymmetry of alveolar ridges, the difficulties connected with that treatment and the suitable techniques and approaches to overcome those problems.