

minimize distortion of ridge and border tissues. *J. Prosthet. Dent.* 1985, 54, 660-66

6. Sharry J. H. Complete denture prosthodontics ed.3, New York, 1974, MacGraw - Hill Book Co, pp191-211

7. Watson IB, MacDonald DG. Oral mucosa and complete dentures. *J. Prosthet. Dent.* 1982, 47, 1, 133-40

8. Hadjieva, H., M. Dimova: A selective impression method for edentulous pa-

tients with hypermobile and flabby mucosa., Scientific Researches of the Union of Scientists in Bulgaria - Plovdiv, Series D. Medicine, Pharmacy and Stomatology, vol. VI, 2005, 295-300

Address for correspondence:

Dr. Hrizdana Hadjieva,

Dept. of Prosthodontics, Faculty of Stomatology, Sofia,

tel. +359/888 684 291, +359/29549209, e-mail: hrishadj@abv.bg

Journal of IMAB - Annual Proceeding (Scientific Papers) 2005, book 2

TOTAL REHABILITATION BY EDENTULOUS PATIENTS WITH IRREGULARITY OF THE ALVEOLAR RIDGES

Hrizdana Hadjieva Mariana Dimova
*Department of Prosthodontics, Faculty of Stomatology,
Medical University - Sofia, Bulgaria*

ABSTRACT

Introduction. The treatment of edentulous patients is always a challenge for the prosthodontists. It is connected with a lot of procedures aiming to reconstruct and replace the lost natural dentition and associated structures of the mandible and maxilla for patients who have lost all their remaining teeth. The basic objectives of complete denture Prosthodontics are the restoration of function, facial appearance and the maintenance of patient's health.

The **aim** of this work is the prosthetic treatment of patients with asymmetry of alveolar ridges, the difficulties connected with that treatment and the suitable techniques and approaches to overcome those problems.

Material and methods. Twenty patients, twelve women and eight men, with an average age of 64 ± 7 years were included in this investigation. All of them had different type and degree of irregularity of the alveolar ridges. The complaints of the patients were mainly connected with poor denture stability during mastication and with the esthetics. The treatment strategy of those patients included excellent impression of the peripheral seal, very careful measurement of the parameters of the vertical and horizontal occlusal plane, lingualized occlusion and esthetics improvement procedures.

Results: All the twenty patients accepted the new dentures with comfort and esthetical satisfaction and assessed them to be significantly more satisfying in esthetic

appearance, maxillary and mandibular denture retention and chewing ability. To six of them preliminary contacts were eliminated at the delivery appointment. On the second appointment by 3 patients from the third group and one from the first group decubital ulcers were treated.

Conclusion. As complete dentures are the last consideration for the patient (excluding implant treatment) they must be designed and constructed with an emphasis on the preservation of the remaining structures.

Key words: denture retention, denture esthetics, irregularity of the ridges, edentulousness

INTRODUCTION.

One of the most important factors for the successful result of the prosthetic treatment of fully edentulous patients is the stability of the dentures. Factors, influencing the denture base stability are: the kind and the mobility of the oral mucosa; the kind, stage and asymmetry of the jaws' bone resorption; adhesion of the denture base to the denture bearing tissues; the accurate impression of the border (peripheral) tissues; the shape and the inclination of the slopes of the alveolar ridges and the inter-alveolar angle./1/

The **aim** of this work is the prosthetic treatment of patients with asymmetry of alveolar ridges, the difficulties connected with that treatment and the suitable techniques and approaches to overcome those problems.

MATERIAL AND METHODS

Twenty patients, twelve women and eight men, with an average age of 64 ± 7 years were included in this investigation. All of them had different type and degree of irregularity of the alveolar ridges and subjective complaints mainly connected with poor denture stability during mastication; sense of different strength of contacts at left and right side when closing teeth and with the esthetics. The patients were divided into three groups according their strong subjective complaint. In the first group-the group of strong functional complaints were included three women and four men, in the second group with esthetic strong subjective complaints were six women and one man (Fig. 1.) and in the third group were three women and one man with strong subjective complaints concerning both stability and esthetics.

For the reason of good primary impression all the patients were asked not to wear their old dentures for 2-3 days. From all of the patients anatomic impressions were taken with standard metal tray with reasonable approximation of the size and the shape of the existing anatomic structures and irreversible hydrocolloid as an impression material Ypeen (Spofa Dental).

The resulting stone casts were subjected to analysis to evaluate the kind and the rate of irregularity of the alveolar ridges. The retentive undercuts and bony exostosis were delineated and a spacer - wax was placed there.

The individual trays were performed of autopolymerizing PMMA - Duracrol (Spofa Dental) according to the generally acknowledged requirements. /2/ The impression technique we used comprises an well-adapted individual tray by moderate movements, border molding with Xantopren - function, Heraeus Kulzer, GmbH & Co. KG, and a subsequent wash impression with Xantopren M-mucosa, HeraeusKulzer, GmbH&Co.KG.

The vertical dimensions and the central position of the lower jaw were established as follows. The upper occlusal rim is justified to be parallel to the interpupillary line in the frontal plane and parallel to Camper's line in the sagittal plane. It should be seen no more than 1 mm below the upper lip. Fig. 2. The lower occlusal rim is adjusted to the plane of the upper rim, in height not over the level of the lower lip.

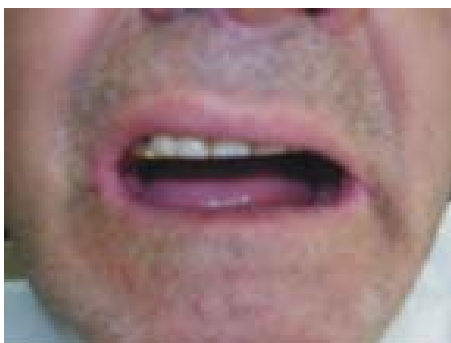


Fig. 1. A patient from the second group-poor esthetic

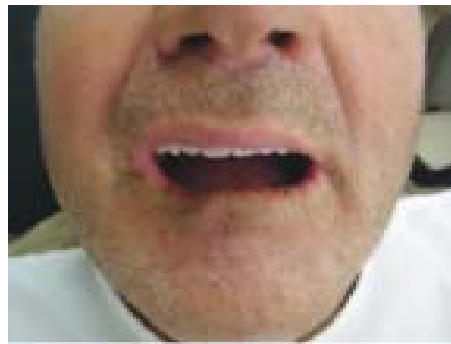

Fig. 2. Correct occlusal plane

We measured first the rest vertical dimension and then reduce it to the occlusal vertical dimension with 2-4 mm. To record the centric relation we remove about 3 mm of the mandibular rim from the first premolar distally to the end of the wax rim both on the right and the left sides. On the maxillary rim in the corresponding areas we cut two or three notches. /3, 4/ At this appointment the size, form and the color of the teeth is chosen, according patients desire and our recommendations. We used "Ivostar" (Ivoclar, Vivadent AG) frontal teeth.

The patients from the second and the third group (esthetical complaints) had an extra try-in appointment with only the frontal teeth arranged.

For the laboratory arrangement of the teeth for the patients from the first and the third group, we indicate the so-called "lingualized occlusion" and 30 degree cusp teeth "Gnatostar" (Ivoclar, Vivadent AG) modified by selective occlusal reshaping and articulating against mandibular teeth with reduced buccal and lingual cusps and a widened central fossa. /4/ Fig. 3., Fig. 4.

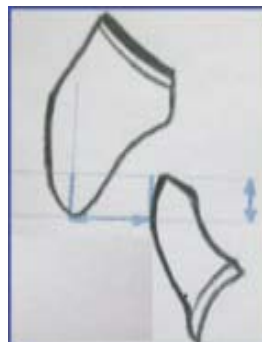


Fig. 3. Vertical and horizontal overlap

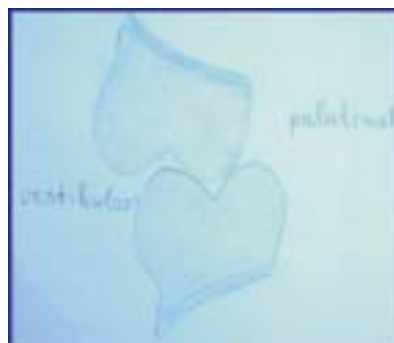

Fig. 4. Lingualized occlusion

At the second try-in appointment, the jaw relations and occlusion were checked and the esthetic appearance approved.

The processed dentures were delivered to the patients and control appointments were settled up at the next day, the third day, after a week and after 1 month.

Subjective data were collected using a visual analog scale that described the patients' satisfaction with the esthetic appearance, the ability to chew, the ability to speak and denture retention was. Objective data were collected on the number of denture ulcers, the number of occlusal contacts and denture retention during eccentric movements.

RESULTS AND DISCUSSION:

All the twenty patients accepted the new dentures with comfort and esthetical satisfaction and assessed them to be significantly more satisfying in esthetic appearance, maxillary and mandibular denture retention and chewing ability. The occlusion was checked. To six of them preliminary contacts were eliminated at the delivery appointment. On the second appointment by 3 patients from the third group and one from the first group decubital ulcers were treated. On the next control appointments all patients reported for good comfort and pleasant esthetics and no corrections were made.

The following moments of the treatment of the edentulous patients with irregularity of the alveolar ridges are critical for the good results:

1. A resin tray should be used which offers excellent rigidity, ease and rapidity of fabrication and adjustment, and minimal dimensional distortion. Custom tray fabrication and adaptation is one of the most important aspects of complete-denture impression procedures for patients with irregularity in the alveolar ridges.

2. Of great importance was the adjustment of the individual tray and the functional impression of the jaws, as that stage influences both stability and esthetics of the patients. All frenuli and ligaments should be free enough to allow free movements of the perioral tissues

3. To eliminate the effect of the irregular form of the alveolar ridges at the frontal parts during the appointment of determining the occlusion, special attention was carried in adjustment of the occlusal plane and the positions of the lips. Wax was added to achieve the right fullness of the lip

and its symmetry to the sagittal plane. The wax rims should be developed with great care to fill the space once occupied by the patient's natural teeth.

4. Measuring the vertical relation of occlusion we make with the upper recording baseplate and the wax rim in the mouth and with the established position of the lip.

5. To allow corrections connected with the esthetics in the frontal part and not to involve into it the posterior teeth arrangement we made an extra wax try-in appointment for the patients with esthetical complains - the second group.

6. Attention was put on the horizontal and vertical overlap of the frontal teeth, which affects extremely denture stability during protrusion and laterotrusion. The vertical overlap should be no more than 0,5 mm and the horizontal between 1,5 - 2 mm.

7. Although not ideal, lingualized occlusion is a valuable concept because it is adaptable to different clinical situations. This is entirely appropriate because a denture is a rigid piece of plastic that must be acceptable anatomically while functioning under the mechanical and physical laws of the constantly changing oral environment. In that lingualized arrangement of the distal teeth the maxillary buccal cusps are raised above the occlusal plane and play no functional role in occlusion. They are present to improve esthetic appearance of the prosthesis and to lift the cheek away from the occlusal plane to prevent cheek biting. The use of 30 degree cusp teeth, modified by selective occlusal reshaping of the vestibular cusps of maxillary teeth and articulating against mandibular teeth with reduced buccal and lingual cusps and a widened central fossa facilitates the movements in all directions.

CONCLUSIONS:

The edentulous mandible and maxillae have different resorption patterns and rarely the reduction of the residual ridges is equal and even so that the ridges remain aligned and parallel. The functional impression, the correct occlusal plane, the exact repositioning of the mandible, the individual arrangement of the frontal teeth and the use of lingualized occlusion are the factors of primary importance for the successful results of complete dentures by patients with irregularity of the alveolar ridges.

REFERENCES:

1. Boyanov, B., V. Kurlyandski. Treatment of edentulous jaws. *Medicina i fizikultura*, Sofia, 1964
2. Ralev, R., Filtchev, A. *Propaedeutics of Prosthetic Dentistry*, Sofia 2000, p. 365
3. Fayz, F., Eslami, A. Determination of occlusal vertical dimension: A literary review. *JPD*, 1988, 59, 3, 321-323
4. Winkler, S. *Essentials of Complete Denture Prosthodontics*, second ed. PSG Publishing Company, Inc. Massachusetts, p.190-193
5. Levin, B. A review of artificial posterior tooth forms including a preliminary report on a new posterior tooth. *JPD*. 1977, 38:3-15

Address for correspondence: Dr. Hrizdana Hadjieva, Dept. of Prosthodontics, Faculty of Stomatology, Sofia, tel. +359/888 684 291,+359/2/954 92 09, e-mail: hrishadj@abv.bg