

STOMATITIS PROSTHETICA-A POLYETIOLOGIC DISORDER

Brizdana Hadjieva, Mariana Dimova, S. Todorov
Department of Prosthetic Dentistry, Faculty of Stomatology,
Medical University-Sofia, Bulgaria

ABSTRACT:

Introduction. The prosthetic stomatitis is a multietiological condition. The clinical manifestation could be the same nevertheless what is the etiology and at the same time one and the same reason could result in different clinical manifestation.

The **purpose** of this investigation is to establish the frequency of denture stomatitis, its etiology, diagnosis and treatment.

Materials and methods. The authors have investigated 300 patients with removable complete and partial dentures. The patients with denture stomatitis were 54. All of these 54 patients were subjected to microbiologic tests and tests for allergy to pink and clear polymethylmethacrylate. The quality of the prosthetic treatment was checked: the extension of the borders, the vertical occlusal distance, the occlusion and the dentures' fit to the underlying mucosa.

Results: From all 300 patients 54 (18%) were diagnosed with prosthetic stomatitis. By 18 patients (6%) we established oral candidosis, and by 12 patients (4%) we observed positive allergic tests. By 18 patients (6%) the reason for the inflammation was due to trauma from the prostheses. By 27 patients (9%) the denture and oral hygiene were unsatisfactory.

Summary: Denture stomatitis is not a rare condition. Its treatment will be successful if only the etiologic factor or factors are established.

Key words: denture stomatitis, allergic stomatitis, trauma from dentures, Candida associated denture stomatitis

Denture stomatitis is a common inflammatory condition that affects denture wearers. In otherwise healthy individuals it usually manifests itself as an erythematous, edematous mucosa underlying and confined to the area covered by a complete upper denture. It is sometimes found under upper partial dentures, but only rarely beneath mandibular dentures. Symptoms are rare: a mild burning sensation is reported, depending on the type of the food, and very rarely dysphagia.

Three types of denture stomatitis have been described. [5]

Newton's type I – a localized simple inflammation, described as 'pinpoint hyperemia', which manifests as discrete focal areas of inflammation of the palate.

Newton's type II – generalized erythema involving the whole area covered by the denture.

Newton's type III – papillary hyperplasia of the palate.

The prevalence of denture stomatitis among complete denture wearers has been shown to be from 25% to 65% depending upon the type of sample population chosen by various researchers. [4, 6] It is therefore a very common condition in the denture wearing population.

Classically the causes of denture stomatitis have been cited as: denture trauma, poor oral and denture hygiene, 24-hour denture wearers, fungal infections and hypersensitivity to denture base materials. [1-6]

The primary **aim** of this investigation is to determine the frequency of denture stomatitis and to establish the relative significance of trauma, infection with *Candida albicans* and allergy in the etiology of denture stomatitis.

MATERIAL AND METHODS:

The present investigation included 300 patients (170 women and 130 men) with full or partial dentures attending the department of Prosthetic dentistry in the faculty of Stomatology in Sofia for provision or replacement of removable dentures. The patients had no complaints but only 6 women complained of slight burning and itching sensation especially provoked by intake of hot and spicy food. All of them were subjected to extra oral and intraoral observation and the state of oral mucosa and the cleanliness of the dentures were established.

A qualitative differentiation of the inflammatory intensity were made by those with observed inflammation of the mucosa, distinguishing between, slightly inflamed, moderately inflamed and severely inflamed mucosa. [4]:

Slightly inflamed: slight erythema, scraping with a spatula does not produce any reaction of pain

Moderately inflamed: distinct erythema, scraping with a spatula produces a reaction of pain

Severely inflamed: the mucosa is fiery red, scraping with a spatula produces a reaction of pain and bleeding of the mucosa involved.

From the patients with observed inflammation of the mucosa (54 patients) a medical and dental history was recorded with special reference to factors which might dispose to denture stomatitis: antibiotic therapy, systemic diseases (endocrine deficiencies, iron-deficiency anemia), edentulous age, age and number of dentures, denture usage and denture brushing frequency.

An examination of the denture cleanliness was made using a plaque detector to disclose the plaque on the fitting surface of the denture with 1% of fuchsin. According to the quantity of plaque on dentures, patients could be divided into three groups using the following index of denture cleanliness [4]:

Excellent: none or only few spots of plaque.

Fair: more extended plaque, less than half of the denture base covered by plaque.

Poor: more than half of the denture base covered by plaque.

On all the patients with established denture stomatitis the mouth was examined for Candida infections.

Dermal "patch tests" to pink and clear PMMA were performed by patients with denture stomatitis.

All patients with inflamed mucosa were checked for occlusion, vertical dimensions and fit of the dentures to the palatal mucosa. The occlusion was controlled by articulation paper, the vertical dimension by measuring the interocclusal distance and the fit of the denture by pressure indicating paste.

RESULTS AND DISCUSSION:

From all 300 patients we observed 54 patients with denture stomatitis (18%), 39 women (72,22%) and 15 men (27,78%). Only 6 women (11,11%) with denture stomatitis complained of slight burning and itching sensation, especially provoked by intake of hot and spicy food. Four women and two man (11,11%) had severe inflammation of the palate, with marked papillomatosis and angulus oris. /Fig.4 and Fig 3/. Twelve women and six men were with moderate stomatitis (33,33%) / Fig 2/ nineteen women and eleven men were with slight inflammation (55,56%). / Fig.1/

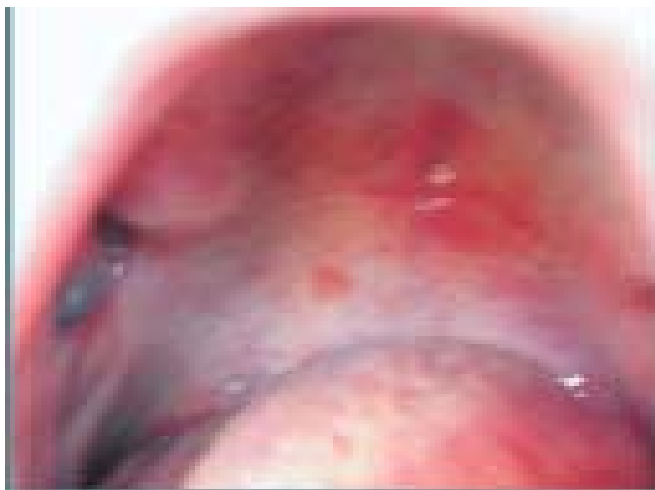

Fig. 1 Slight inflammation

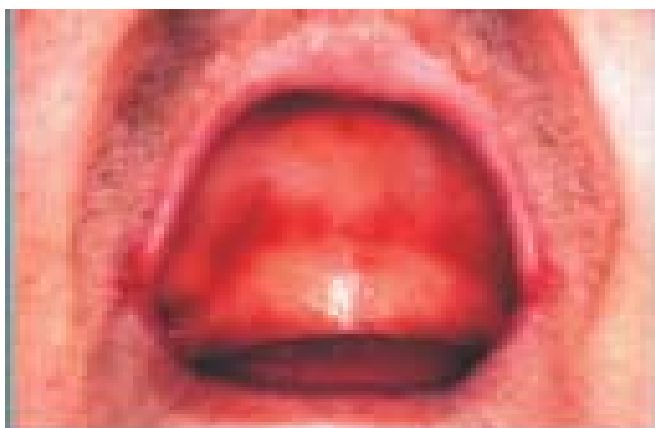


Fig. 2 Moderate inflammation

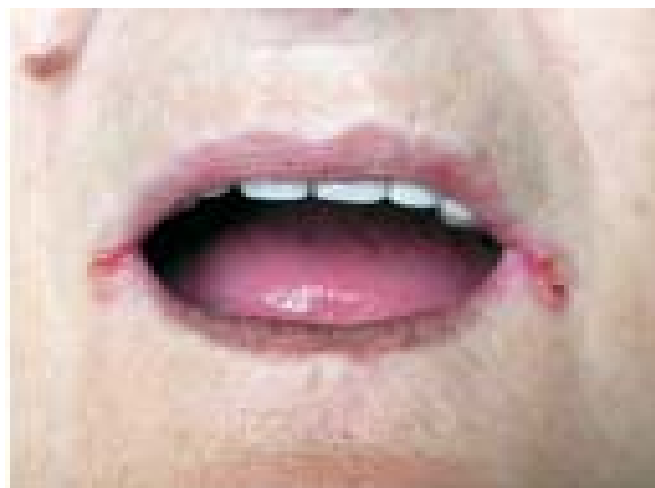

Fig. 3 Angulus oris

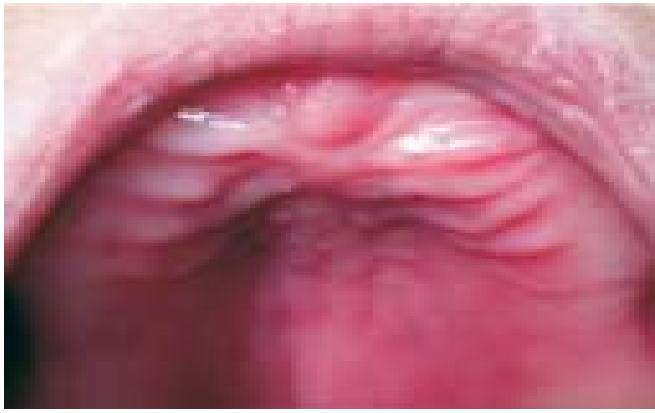


Fig. 4 Severe inflammation

A microbial plaque will form on any appliance placed in the mouth and 'denture plaque' held against the underlying mucosa may be a cause of trauma. [1,6] The incidence of denture stomatitis has been shown to be higher in individuals with poor oral/denture hygiene but not 100%. Some patients with denture stomatitis apparently have very good denture hygiene.

By patients with denture stomatitis (54) we observed poor denture hygiene by 30 patients (55,56%).

Obviously it's not a 'normal' state to wear dentures and the dentures will have some effect on their local environment, which may predispose toward denture stomatitis. However, the denture alone is not the cause because not all denture wearers develop denture stomatitis. Denture trauma has often been cited as a possible contributory factor and it is true that poorly fitting dentures, those with incorrect jaw relationships or occlusal errors can damage the supporting tissues. [4,6]

All 54 patients were subjected to examination of the occlusion, vertical dimension and pressure under the prostheses. We established that by 24 patients (44,45%) there were significant errors with the occlusion end by 12 of them (22,22%) as well with the vertical dimensions. The pressure under the prostheses was unfavorable by 30 patients (55, 5%), from which was due the ill fitting denture base to the oral tissues.

Denture stomatitis is also known by various other names e.g. chronic atrophic candidiasis, Candida associated denture stomatitis and denture induced candidosis. However the infection with Candida is not the sole cause of denture stomatitis as the condition will not develop without a denture being present and will resolve if the denture is removed. Various studies have shown Candida species to be present in up to 60% of healthy individuals and other believe that they are actually human commensals, i.e. present in 100% of the population. [2,4,6]

The mycological results showed that 18 patients (33,33%) were positive for *Candida albicans* in the range

of 104 to 105.

Allergy to modern denture base materials is very rare. Residual monomer of methyl methacrylate is known to be an irritant to mucosal tissues, but the residual monomer content in properly processed denture base is so small that it would be unlikely to cause problems and would leach out of the dentures soon after it was first inserted. [3]

Our results show that 12 patients (22,22%) had positive patch test for pink polymethylmethacrylate (PMMA), 10 with one plus measured at the 48h and two patients with tree plusses. All patients showed negative patch test to clear PMMA.

CONCLUSIONS:

Although denture stomatitis is usually asymptomatic, and patients often unaware they have this condition, an inflamed edematous palatal mucosa is not healthy. If left untreated it may progress to papillary hyperplasia, which can only be resolved surgically. Every effort should be made to restore the healthy palate, especially if this can be achieved by simple modifications to the denture and patient's wearing habits. Also it would be unwise to make a new denture with denture stomatitis present as not only may the fit of the denture be compromised but also the new denture would propagate the condition.

The existing dentures should be examined and any obvious faults corrected. This may necessitate making new dentures, but only after the denture stomatitis has resolved. It has been shown that *Candida* species can colonize the surface of the dentures. Temporary soft lining materials should not be used as they act as reservoirs for the microorganisms and are difficult to disinfect. If the dentures do not fit properly then a chair side hard relined material should be used. resin.

The importance of denture and oral hygiene must be stressed and the patient given instruction. The fitting surface of the denture acts as a reservoir for the fungal organisms. It is important to first thoroughly clean the denture by brushing and then soak in a disinfecting solution, preferably overnight. Chlorhexidine gluconate mouthwash is effective for this purpose, and the patient can also rinse with it while the dentures are out of the mouth [1]. Weak hypochlorite solution (a few drops of ordinary household bleach in a denture pot filled with water) can also be used for acrylic dentures, but not for metal dentures where it will cause tarnishing.

The patient must be encouraged to leave their dentures out at night.

If the above measures have been instituted by the patient and the stomatitis fails to resolve, or if fungal involvement has been confirmed by mycological diagnosis, antifungal therapy can be given. Although topical antifungal treatment tends to be prescribed it should be

realized that the yeasts may be present throughout the gastrointestinal tract and that this should also be treated. Usually Nystatin (4 x 100, 000 IU, for 7 days tablets and suspension) and Fluconazol (1x50 mg for 14 days, capsules and suspension) are prescribed with almost equally effectiveness. The patients should be informed about the local use of the antifungal drugs that these are dissolved slowly in the mouth after removing the dentures.

Summary:

The observed frequency of denture stomatitis by us is 18%.

Women suffer more often than man, twice more in our observation.

The evidence for the etiology of denture stomatitis

is inconclusive and often contradictory. The etiology is probably multifactorial, and there may be as yet undiscovered mechanisms operating, which predispose towards this condition.

Provisional diagnosis of denture stomatitis is based on clinical signs, as symptoms are rare. The treatment should begin with thorough examination of the dentures and corrections of the faults if possible. If a new denture is needed first the inflammation must be treated. If fungal proliferation is suspected mycological investigation should be undertaken, especially if antifungal therapy is to be

Patch tests should be made by patients with allergic history and by those, whose other treatment gives no reliable results and there are frequent recoveries of the condition

REFERENCES:

1. Stoyanova, O., M. Pasheva, B. Stoev. Candidal prosthetic stomatitis and denture disinfection. Stomatology, S, N 4, 1983, p. 33-37
2. Arrendorf, T. M. and Walker, D. M. Oral candidal populations in health and disease. Br. Dent. J. 1979, 147, 267-272
3. Baurle, G. Allergologische Risiken durch Prothesenwerkstoffe- Eine klinische Studie. Dtsch. zahnärztl. Z. 37, 1982, 787-791
4. Budtz-Jørgensen, E. and Bertram, U. Denture stomatitis. The etiology in relation to trauma and infection. Acta Odontol. Scand. 1970, 28, 71-92
5. Newton, A. V. Denture sore mouth. A possible etiology. B. Dent. J. 112, May 1, 1962, 357-360
6. Turrell, A. J. Etiology of inflamed upper denture-bearing tissues. Br. Dent. J., 1966, June 7, 542-6

Adress for correspondence:

Dr. Hrizdana Hadjieva, PhD,
Dept. of Prosthodontics, Faculty of Stomatology - Sofia,
1, St. G. Sofiiski str., 1359 Sofia, Bulgaria
e-mail: hrishadj@abv.bg
marianadimova@abv.bg