

Tc-99m MIBI SPECT AND CT NEUROIMAGING IN PATIENT WITH TUMOR-ASSOCIATED POSTOPERATIVE REFRACTORY SEIZURES: IS IT A TUMOR RELAPSE

Ara Kaprelyan, N. Deleva, P. Bochev*, A. Klissarova*, G. Kuchukov**, I. Dimitrov

*Department of Neurology; *Department of Radiology and Nuclear medicine;*

***Department of Neurosurgery,*

Prof. Paraskev Stoyanov Medical University of Varna, Bulgaria

ABSTRACT

Seizures are the presenting symptom in about 20% to 40% of patients with brain tumors and occur in about half of them during the course of the disease. Mixed gliomas, oligodendrogliomas and astrocytomas are most frequently associated with epilepsy. In patients with postoperative seizures neuroimaging should be performed to exclude tumor recurrence. We reported a case of 56-years old female admitted to our hospital with clinical signs of increased postoperative partial seizures activity and mild focal deficit. Medical history revealed that patient became symptomatic by brain tumor with sudden onset of generalized tonic-clonic seizure sixteen years ago. A low-grade astrocytoma was verified histologically after surgery. Ten years later the patient experienced right-sided partial motor and sensory seizures. Antiepileptic therapy was initiated and temporary good control of epilepsy was achieved. Current EEG findings showed left frontotemporal focus of epileptic activity. On contrast-enhanced CT scans no recurrent tumor mass was visualized. Brain SPECT images demonstrated no Tc-99m MIBI uptake. Despite the clinical presentation of refractory partial seizures, tumor recurrence was not detected. Based on the literature analysis and our own data, different etiological mechanisms underlying tumor-associated epilepsy were discussed.

Key words: Tc-99m MIBI brain SPECT, CT scan, tumor-associated epilepsy, refractory seizures, tumor relapse, etiological mechanisms

INTRODUCTION

According to the literature, seizures occur in about half of patients with brain tumors during the course of the disease (2, 6, 8, 9, 13). They may be focal or generalized and clinical manifestation includes motor, sensory, visual or behavioral changes (16, 17, 18, 21, 23). The seizures type and incidence depend on the location, size and the histology of the tumor. Tumors involving the frontal, frontoparietal, temporal and frontotemporal lobes are most commonly associated with occurrence of seizures (1, 2, 6, 8, 18).

Previous studies report that patients with mixed gliomas, oligodendrogliomas and astrocytomas experience seizures most frequently (1, 12, 14, 24, 25). Etiological mechanisms underlying tumor-associated epilepsy include cerebral edema, local metabolic imbalances, and changes in neuronal and glial enzyme expression, altered immunological activity etc. (6, 16, 17, 24). In patients with postoperative seizures, particularly in the presence of therapeutic anticonvulsant level, neuroimaging should be performed to exclude tumor recurrence or hemorrhage (3, 4, 5, 7, 10, 11, 20).

CASE PRESENTATION

We reported a case of 56-years old female who experienced increased postoperative partial seizures activity within the last three months. Clinical examination found mild right-sided facial palsy, hemiparesis, hemihypesthesia and cognitive deficit (MMSE - 24 points). Past medical history revealed that patient became symptomatic by brain tumor 16 years ago, with sudden onset of generalized tonic-clonic seizure. Initial CT images visualized a tumor lesion in the left frontotemporal region. Surgery was performed and histological verification showed features of low-grade astrocytoma. Ten years after the operation the patient remained seizure free. Partial motor and sensory seizures with or without secondary generalization developed later. Electroencephalography (EEG) demonstrated an epileptic discharge in left frontotemporal region. CT scans follow-up showed no evidence of recurrent tumor. Antiepileptic therapy was initiated and temporary good control of epilepsy was achieved. Based on the medical history and clinical data, a possible tumor relapse was suggested. Current EEG findings showed left frontotemporal focus of epileptic activity (Fig.1). On contrast-enhanced computed tomography (CT) scans no recurrent tumor mass appeared (Fig.2). Brain single photon emission computed tomography (SPECT) images demonstrated no Tc-99m MIBI uptake (Fig.3). Despite the clinical presentation of refractory partial seizures, no tumor recurrence was detected.

DISCUSSION

There is increasing evidence that brain tumors are the second most common cause (6 -11 %) of epilepsy (13, 16, 17, 24). Focal and/or generalized seizures may occur as an initial sign or a late onset in about 40% to 60% of patients (1, 15, 17, 19). Their symptomatology depends on the localization, size and histology of the neoplastic lesion (16, 19, 24).

Recent studies present data that seizures are associated most frequently with slow growing tumors, involving mixed gliomas (62%), oligodendrogliomas (53%) and astrocytomas (42%) (8, 13, 14, 16). Perirolandic cortex and medial temporal structures, followed by other areas of frontal, temporal and parietal lobes are considered to be the most epileptogenic (2, 6).

The literature analysis suggests that in patients with abrupt increase in frequency and severity of late postoperative seizures, despite therapeutic anticonvulsant levels, a structural change in tumor should be suspected (11, 26). In these cases, CT scan or MRI and additional functional neuroimaging studies should be performed to identify a possible tumor recurrence or hemorrhage (5, 7, 8, 22, 24, 27, 29). Patients' evaluation includes also clinical data and complimentary assessment of EEG findings (8, 9, 22, 27). In accordance with these facts we performed also structural scans and brain SPECT. Although clinical signs and EEG findings in our patient were suspicious for tumor recurrence the neuroimaging results were negative, a fact that suggested another underlying epilepsy mechanisms.

According to the literature, the increased electrical activity of the neurons in a seizure focus can be due to altered properties of the neurons, altered synaptic connections between neurons, or altered conditions surrounding the neurons (2, 11, 18, 28). There is also evidence, however, that seizures in the setting of a brain tumor may be due to alterations in the brain tissue surrounding the tumor, rather than within the tumor. In addition, our data suggested that possible etiological mechanisms of tumor-associated epilepsy might be local metabolic imbalances, changes in neuronal and glial enzyme expression or altered immunological activity.

In conclusion, based on the literature analysis and our own past and present data we suggest that low-grade astrocytomas are among the most frequently brain tumors associated with epilepsy. Most commonly they are localized in the frontal and/or temporal regions and cause focal motor and/or sensory seizures. Different etiological mechanisms underlying tumor associated-epilepsy are discussed including peritumoral amino acid disturbances, local metabolic imbalances, cerebral edema, pH abnormalities, changes in neuronal and glial protein expression and altered immunological activity. Although the mechanisms of tumor-related epileptogenesis remain unclear, in patients with postoperative seizures tumor relapse should be considered. Therefore, evaluation of clinical data, EEG findings, structural scans, pathological diagnosis and post-surgical follow-up is necessary. The more so as tumor-associated epilepsy has important clinical, social and economic implications.

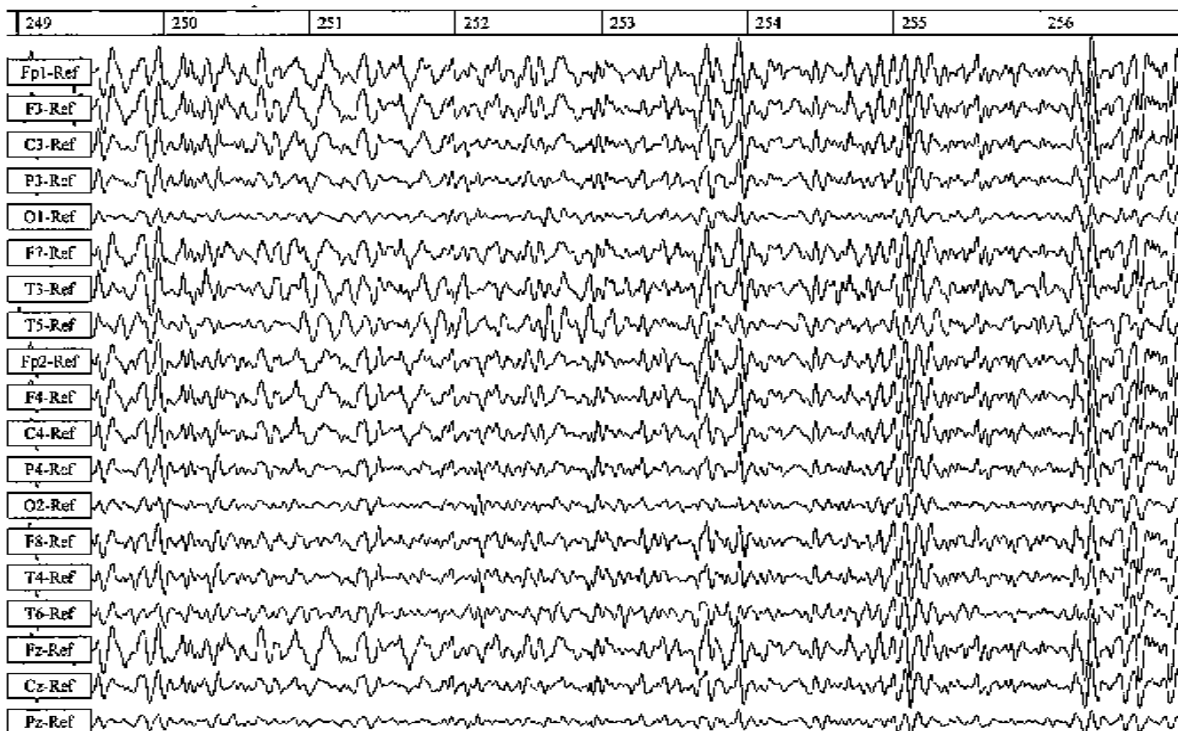


Fig. 1. EEG findings shows left frontotemporal focus of epileptic activity.

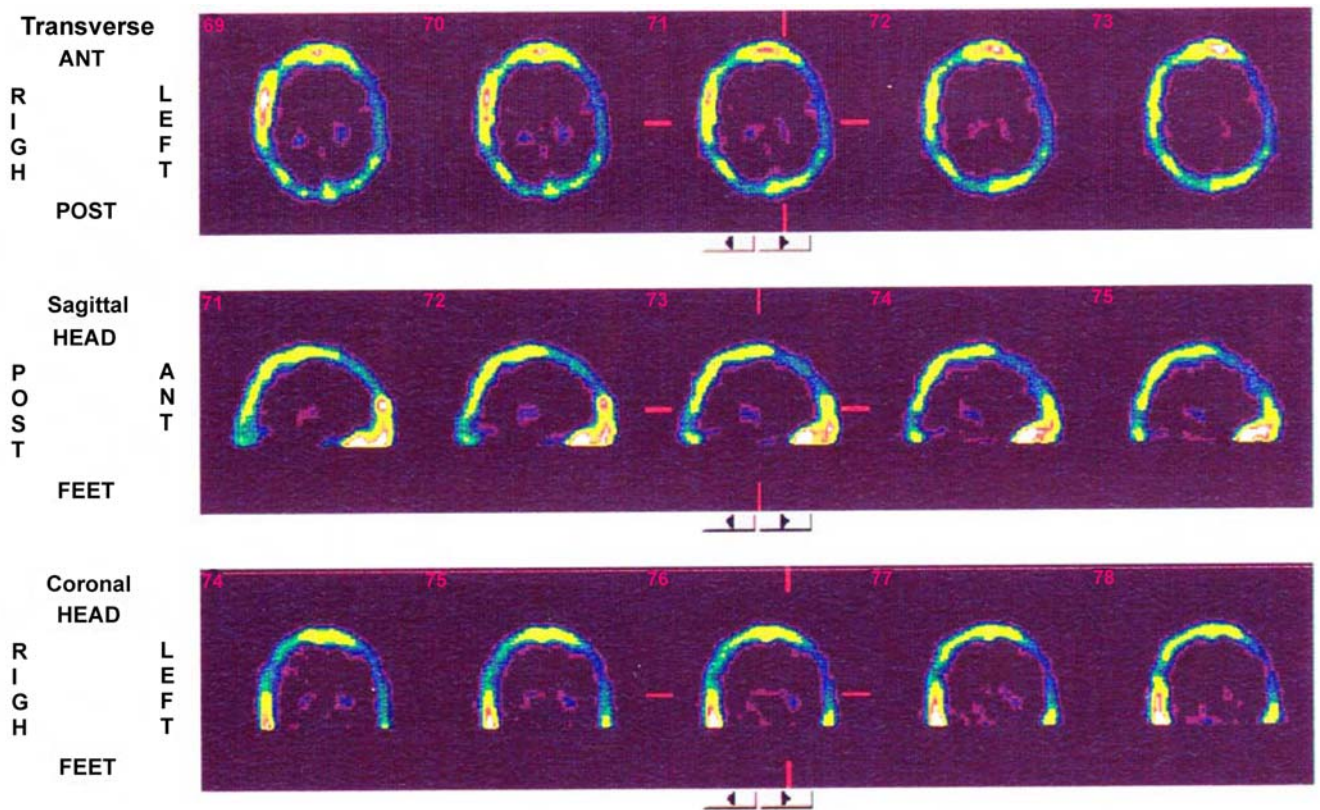


Fig. 2. Brain SPECT image demonstrates no Tc-99m MIBI uptake.

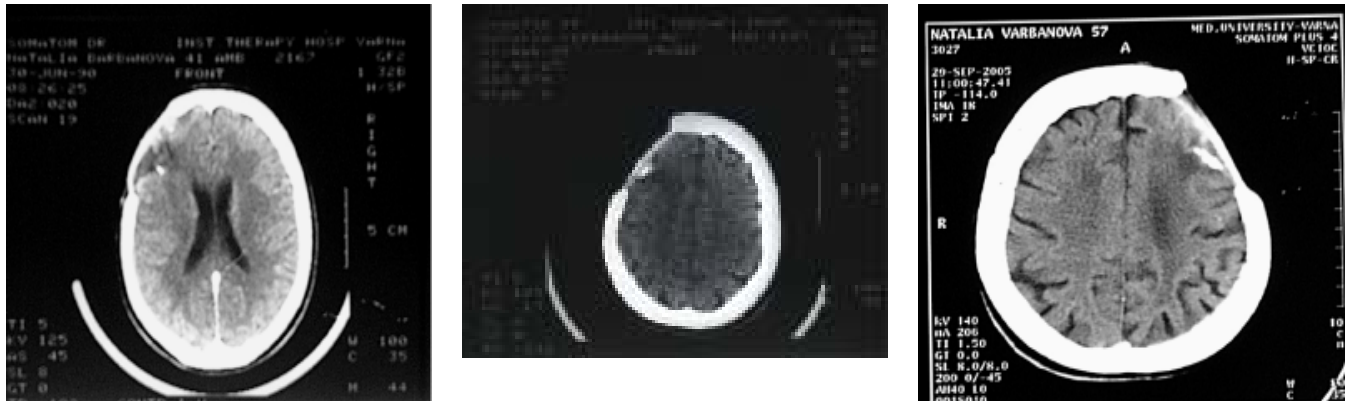


Fig. 3. CT scans show no recurrent tumor mass.

REFERENCES:

1. Минчев Д., Капрелян А., Генева С., Ковачев Ст. Епилептичен синдром при болни с тумори и съдови заболявания на главния мозък: клинично-диагностични проблеми. Годишен сборник (научни трудове) ИМАБ, 1, 1995, 1, 49-51.
2. Цеков С., Минчев Д., Киров Ф. Епилепсия и мозъчни тумори. Клинично-терапевтични проблеми. В: Живот в равновесие. X-та юбилейна конференция по епилепсия, Екофарм ЕООД, София, 2004, 73-74.
3. Vagni B, Pinna L, Tamarozzi R, et al. SPET imaging of intracranial tumours with ⁹⁹Tcm-sestamibi. Nucl. Med. Commun., 4, 1995, 16, 258-264.
4. Baillet G., Albuquerque L., Chen Q., Poisson M., Delattre J. Evaluation of single-photon emission tomography imaging of supratentorial brain gliomas with technetium-99m sestamibi. Eur. J. Nucl. Med., 10,

- 1994, 21, 1061-1066.
5. Barai B., Bandopadhyaya G., Julka P., Malhotra A., Haloi A., Naik K. Brain Tumor Imaging with Tc-99m-Ethylenedicysteine. *I. J. N. M.*, 2, 2005, 20, 45-48.
 6. Beaumont A. The pathogenesis of tumour associated epilepsy. *Acta Neurochir. (Wien)*, 2000, 1, 142, 1-15.
 7. Goethals I., De Winter O., Dierckx R., et al. False-negative Tc-99m MIBI scintigraphy in histopathologically proved recurrent high-grade oligodendroglioma. *Clin. Nucl. Med.*, 4, 2003, 28, 299-301.
 8. Hildebrand J. Supportive care. Management of epileptic seizures. *Curr. Opin. Oncol.*, 4, 2004, 16, 314-317.
 9. Hildebrand J., Lecaille C., Perennes J., Delattre J. Epileptic seizures during follow-up of patients treated for primary brain tumors. *Neurology*, 2005, 2, 65, 212-215.
 10. Hustinx R., Alavi A. SPECT and PET imaging of brain tumors. *Neuroim. Clin. N. Am.*, 1999, 9, 751-766.
 11. Hwang S., Lieu A., Kuo T., et al. Preoperative and postoperative seizures in patients with astrocytic tumours: analysis of incidence and influencing factors. *J. Clin. Neurosci.*, 5, 2001, 8, 426-429.
 12. Jeune F., Dubois F., Blond S., Steinling M. Sestamibi technetium-99m brain single-photon emission computed tomography to identify recurrent glioma in adults: 201 studies. *J. Neurooncol.*, 2, 2006, 77, 177-183.
 13. Kawasaki M. Epilepsy and cerebral tumor. *Rev. Neurol.*, 11, 1999, 28, 1047-1049.
 14. Lima P. Refractory epilepsy associated with cerebral tumor of slow growth. *Arq. Neuropsiquiatr.*, 2001, 4, 59, 983.
 15. Luyken C., Wilmcke I., Fimmers R., Urbach H., Elger C., Wiesler O., Schramm J. The Spectrum of Long-term Epilepsy—associated Tumors: Long-term seizure and tumor outcome and neurosurgical aspects. *Epilepsia*, 6, 2003, 44, 822-830.
 16. Mangano F., McBride A., Schneider S. Brain tumors and epilepsy. In: *Managing epilepsy and co-existing disorders*. Ettinger A., Devinsky O., eds., Boston, Butterworth-Heinemann, 2002, 175-194.
 17. Morris H., Estes M., Gilmore R., et al. Chronic intractable epilepsy as the only symptom of primary brain tumor. *Epilepsia*, 1993, 34, 1038-1043.
 18. Moots P., Maciunas R., Eisert D., et al. The course of seizure disorders in patients with malignant gliomas. *Arch. Neurol.*, 7, 1995, 52, 717-724.
 19. Pace A., Bove L., Innocenti P., Pietrangeli A., Carapella C., Oppido P., Raus L., Occhipinti E., Jandolo B. Epilepsy and gliomas: incidence and treatment in 119 patients. *J. Exp. Clin. Cancer Res.*, 4, 1998, 17, 479-482.
 20. Park C., Kim S., Zhang J., Intenzo C., McEwan J. Tc-99m MIBI brain SPECT in the diagnosis of recurrent glioma. *Clin. Nucl. Med.*, 1, 1994, 19, 57-58.
 21. Peterson K. Brain tumors. *Neurol. Clin.*, 2001, 4, 19.
 22. Sanders W., Christoforidis G. Imaging of low-grade primary brain tumors. In: *The practical management of low-grade primary brain tumors*. Rock J., Rosenblum M., Shaw E. et al., eds., Philadelphia, Lippincott Williams & Wilkins, 1999, 5-30.
 23. Sirven J., Wingerchuk D., Drazkowski J., et al. Seizure prophylaxis in patients with brain tumors: A Meta-analysis. *Mayo Clin. Proc.*, 2004, 79, 1489-1494.
 24. Stefan H., Blumcke I., Buchfelder M. Brain tumors and epilepsy. *Nervenarzt*, 2005, 10, 76, 1196, 1198-200, 1203-4, 1206-1208.
 25. Tandon P., Mahapatra A., Khosla A. Epileptic seizures in supratentorial gliomas. *Neurol. India.*, 1, 2001, 49, 55-59.
 26. Telfeian A., Philips M., Crino P., Judy K. Postoperative epilepsy in patients undergoing craniotomy for glioblastoma multiforme. *J. Exp. Clin. Cancer Res.*, 1, 2001, 20, 5-10.
 27. Wen P., Marks P. Medical management of patients with brain tumors. *Curr. Opin. Oncol.*, 3, 2002, 14, 299-307.
 28. Wick W., Menn O., Meisner C., et al. Pharmacotherapy of epileptic seizures in glioma patients: who, when, why and how long? *Onkologie.*, 28, 2005, 8-9, 391-396.
 29. Yamamoto Y, Nishiyama Y, Toyama Y, Kunishio K, Satoh K, Ohkawa M. 99mTc-MIBI and 201Tl SPET in the detection of recurrent brain tumours after radiation therapy. *Nucl. Med. Commun.*, 12, 2002, 23, 1183-1190.

Address for correspondence:

Dr. Ara Kaprelyan, PhD, Department of Neurology,
 Prof. P. Stoyanov Medical University of Varna,
 55 Marin Drinov Street, BG-9002 Varna, Bulgaria
 E-mail: arakapri07@yahoo.co.uk