

TREATMENT OF PERFORATED INFECTIOUS CORNEAL ULCERS WITH PENETRATING KERATOPLASTY

Ch. Balabanov, Sn. Murgova, B. Parashkevova
Eye Clinic,

University Hospital "Dr George Stranski" - Pleven, Bulgaria

ABSTRACT

Introduction: Corneal perforation due to keratitis requires penetrating keratoplasty to preserve eye integrity, eradication of the infectious process and visual rehabilitation.

Purpose: To evaluate anatomical and functional outcomes of urgent penetrating keratoplasty in perforated infectious corneal ulcers.

Patients and methods: Five consecutive patients (5 eyes) who underwent therapeutic penetrating keratoplasty (PK) for perforated infectious corneal ulcers during a 2 year-period (2004-2006) were followed-up for a mean period of 8.5 months. All patients underwent penetrating keratoplasty by a similar method. In one case a triple procedure including implantation of intraocular lens was performed.

Results: Anatomical integrity was achieved in all five eyes perforated by corneal disease. Clear grafts were obtained in 80% (4 eyes) and semi-transparent in 20% (1 eye). Four eyes obtained a final best corrected visual acuity between 0.2 and 0.9; in one eye it was unchanged due to mature cataract and secondary glaucoma. In the latter case, glaucoma surgery was performed 4 months after PK.

Conclusion: Our results confirm that therapeutic penetrating keratoplasty for keratitis, especially in corneal perforation, is successful in restoring anatomic integrity and visual rehabilitation in most eyes. Without therapeutic surgery, these eyes would have been lost.

Key words: cornea, keratitis, corneal perforation, penetrating keratoplasty

The most common cause of corneal perforation is infection. Bacterial keratitis accounts for 24-55% of all perforations. Tarsorrhaphy, conjunctival flap, application of cyanoacrylate tissue adhesive, sclerocorneal patch and lamellar or penetrating keratoplasty (PK) may be necessary. Large perforations, too large to seal with tissue adhesives or lamellar patch grafting, and smaller perforations surrounded by large areas of tissue necrosis may need penetrating grafts [1]. The first aim of treatment is to maintain the structural integrity of the globe and eradication of the infectious process. Without therapeutic surgery, these

eyes would have been lost (become phthisis after endophthalmitis or required enucleation). Visual rehabilitation is often a secondary objective.

PURPOSE

To evaluate the anatomical and functional outcomes of urgent penetrating keratoplasty in perforated infectious corneal ulcers.

PATIENTS AND METHODS

A retrospective study of five consecutive patients (5 eyes) who underwent therapeutic penetrating keratoplasty (PK) for perforated infectious corneal ulcers at the Eye Clinic, University Hospital - Pleven during a 2 year-period (2004-2006) was performed.

All five patients were hospitalized with corneal perforation in one eye after keratitis.

Microbiological tests were performed immediately. Prior to the operation, oad-spectrum antibiotics - tobramycin and/or Fluoroquinolones (ciprofloxacin or ofloxacin) were applied topically (every hour), subconjunctively, and systemically.

All patients underwent therapeutic penetrating keratoplasty by a similar method.

Postoperatively, the patients were treated with topical antibiotics and lubricants; topical corticosteroid (betamethasone) was applied few days after surgery. Once the acute postoperative period is over, the long-term care is similar to that of uncomplicated PK.

The results were evaluated for each of the following criteria: anatomical integrity of the eye, cure of the disease, complications, graft clarity, and visual acuity.

After PK, graft outcome was defined in terms of the clarity during the follow-up period. The graft was considered to be clear if the clarity was grade 3 or grade 4 (grade 4 for absolutely clear graft with good visualization of the iris details behind it, and grade 3 clarity for a graft with minimal haze but still with good visualization of the iris details). Corneal graft failure was diagnosed when irreversible graft edema was present, with or without vascularization or scarring of the graft.

Intraocular pressure greater than 21 mm Hg on two separate occasions was taken as secondary glaucoma.

All cases were photo documented.

Surgical procedures

All PK had performed under general anesthesia.

A suitable donor cornea was received from the International Eye Bank of Sofia.

Trephination was done per endothelium. The size of the graft should be the smallest capable of incorporating the perforation site and any infected or ulcerated border.

Donor button was oversized by 0.5 mm in all cases and secured with 16 to 20 interrupted 10-0 nylon sutures.

Anterior and posterior synechiolysis, membranectomy (all 5 cases), and pupilloplasty (case 2 and 4) were performed. The anterior chamber should be irrigated to remove the necrotic or inflammatory debris. Cataract removal with intraocular lens implantation was performed in one eye (case 3) despite the risk of expulsive hemorrhage and endophthalmitis. Fig.1. – Fig.6.

Subconjunctival injection of antibiotics without steroid was given.

SURGICAL TECHNIQUE

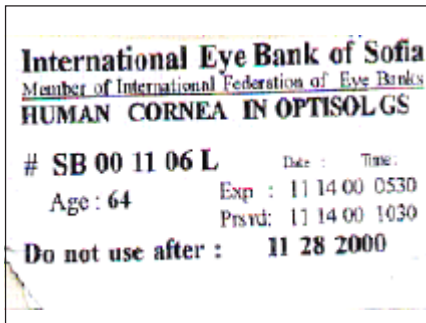


Fig. 1. The Eye Bank

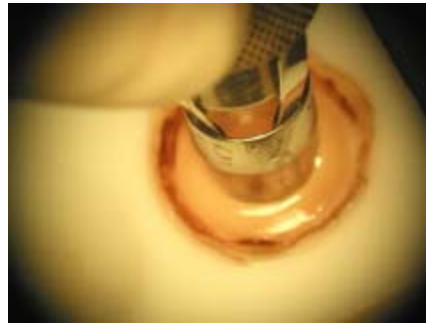


Fig. 2. A corneal graft trephination

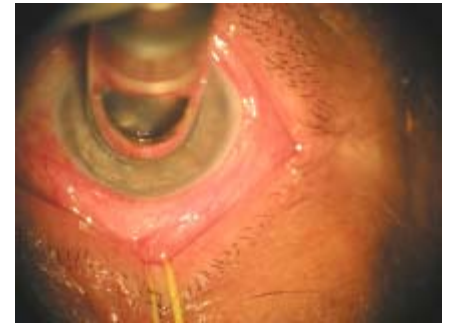

Fig. 3. A host corneal trephination

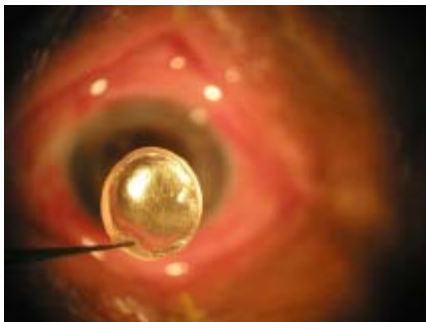


Fig. 4. A donor corneal button

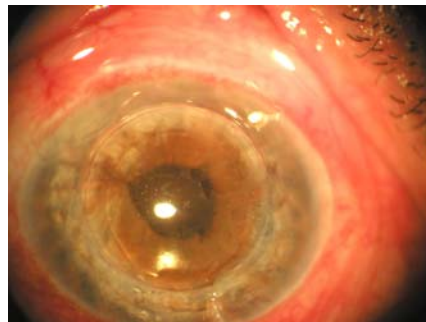


Fig. 5. A graft adaptation

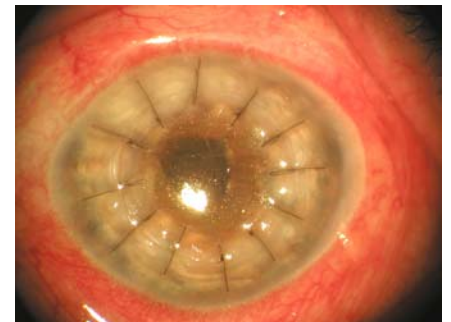


Fig. 6. Interrupt suturing technique

RESULTS

Three of the 5 patients were male and 2 were female, with a mean age 48.2 years (between 18 to 69 years). Three patients were farm workers and 2 had other occupations. The patients arrived at our hospital 5 days to 12 months (average of 4 months) after the onset of the keratitis.

The mean follow-up period was 8.5 months, ranging from 1 to 20 months.

Predisposing conditions leading to infectious keratitis and corneal perforation were trauma in 3 eyes, chronic necrotizing and ulcerative keratitis with unknown etiology in 1 eye, and corneal melt associated with corneal

surgery for pterygium in 1 eye.

Two of the eyes had a central corneal ulcer between 7 and 8 mm in diameter (case 1 and 5), two eyes with eccentric ulcers - between 5 and 6 mm (case 3 and 4) and one eye with eccentric ulcer less than 5 mm (case 2). Three corneas had a single quadrant superficial and deep vascularization, and two with four quadrant of superficial and deep vascularization.

No microorganisms were identified on the preoperative slide smear.

Anatomical integrity was achieved in all the five eyes perforated from corneal disease.

Therapeutic PK cured the disease in all keratitis cases.

Postoperatively, three of the eyes (case 1, 3 and 4)

had a grade 4 clarity of the corneas during the 1 to 8,5 months follow-up period, one achieved a grade 3 clarity after trabeculectomy at five months, and one eye – a grade 2 clarity (case 5). Fig.7. – Fig.21.

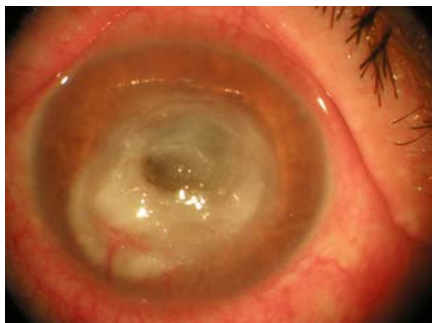

Fig. 7. Case 1 (BSA, 49y): before PK; VOS=PPLC

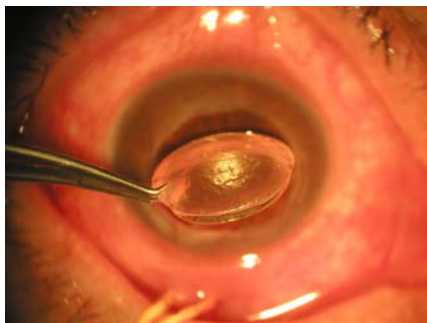


Fig. 8. Case 1 (BSA, 49y): surgery

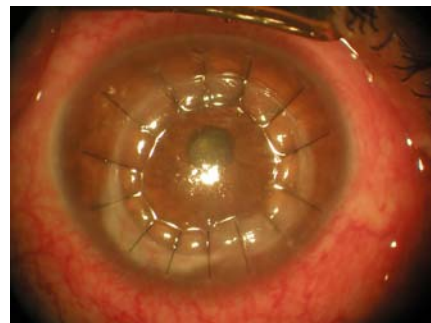


Fig. 9. Case 1 (BSA, 49y): 30 days after PK; VOS=0,2

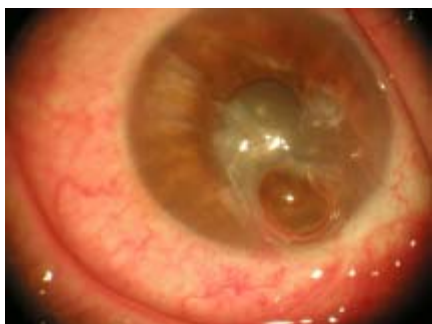

Fig. 10. Case 2 (EIV, 45y): before PK; VOS=PPLC

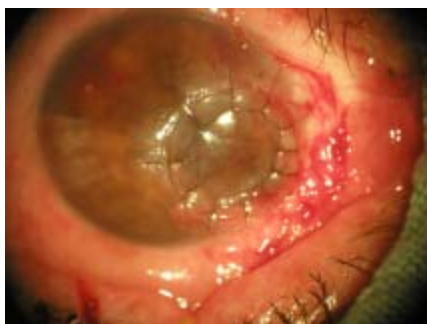

Fig. 11. Case 2 (EIV, 45y): 23 days after PK;

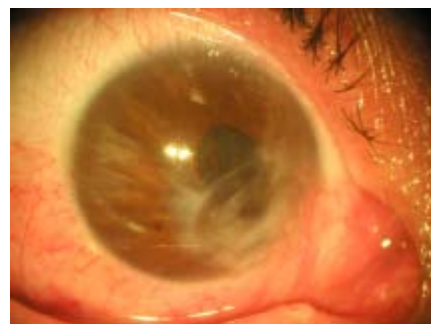

Fig. 12. Case 2 (EIV, 45y): 20 months after PK; VOS=0.8

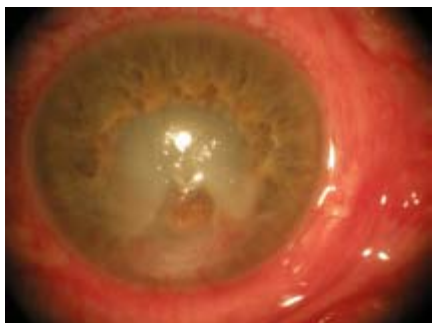

Fig. 13. Case 3 (LPB, 45y): before PK; VOS=PPLC

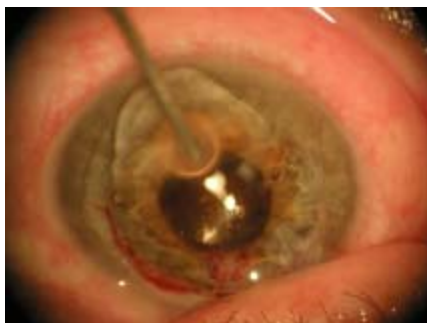

Fig. 14. Case 3 (LPB, 45y): surgery (PK+IOL)

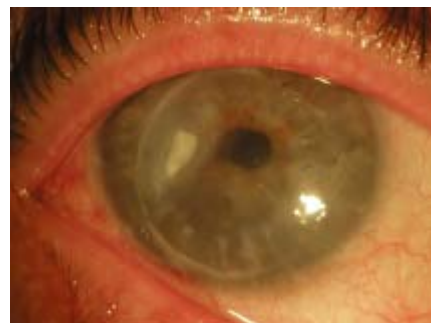

Fig. 15. Case 3 (LPB, 45y): 8,5 months after PK; VOS=0,6

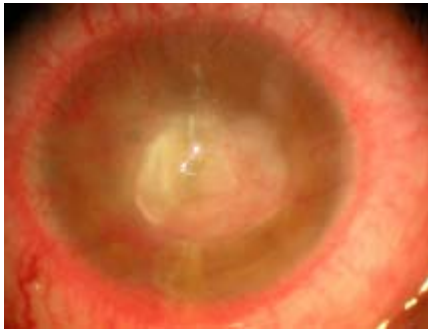


Fig. 16. Case 4 (ZMZ, 18y): before PK; VOS=PPLC

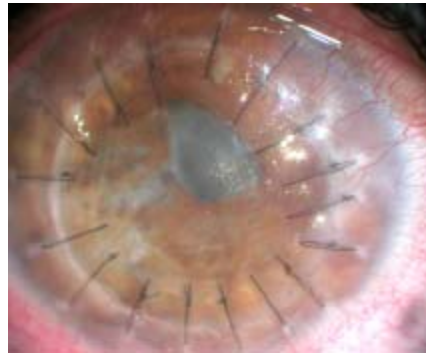

Fig. 17. Case 4 (ZMZ, 18y): 3 months after PK;

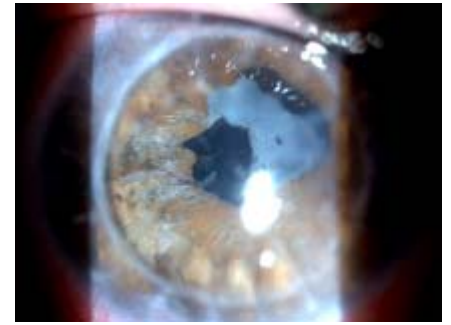

Fig. 18. Case 4 (ZMZ, 18y): 8 months after PK; VOS=0,9

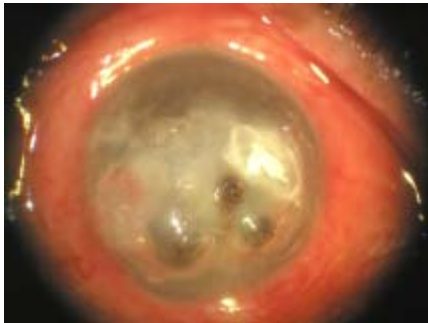

Fig. 19. Case 5 (BSA, 49y): before PK; VOS=PPLC

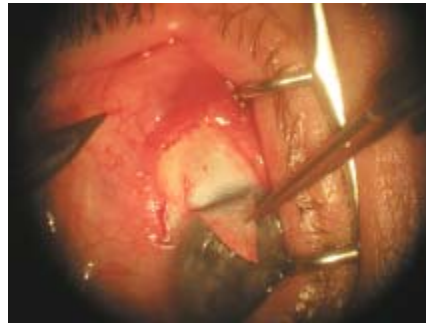


Fig. 20. Case 5 (BSA, 49y): trabeculectomy - 4th month

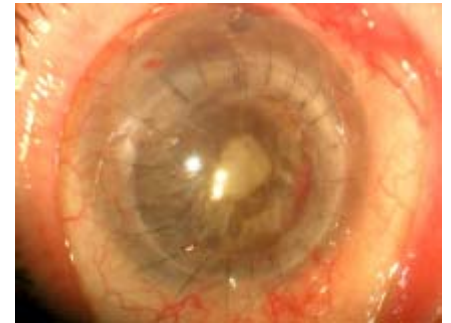

Fig. 21. Case 5 (BSA, 49y): 5 months after PK; VOS=PPLC

The visual acuity results are shown in Table 1.

Tab. 1. Visual acuity of the patients

VISUS	PL, PPL, HM No(%)	HM - 0,04 No(%)	0,05 - 0,1 No (%)	0,2 - 0,4 No (%)	>0,5 No(%)
Before PKP	4 (80)	0 (0)	1 (20)	0 (0)	0 (0)
After PKP	1 (20)	0 (0)	0 (0)	1 (20)	3 (60)

The preoperative visual acuity ranged from light perception to 0.05. Postoperatively, the best corrected visual acuity among the 4 clear grafts ranged from 0.2 to 0.9. Only one eye with a grade 3 clarity cornea didn't change visual acuity because of a mature cataract and compensate glaucoma (case 5). In case 2, despite a grade 2 clarity, the visual acuity was 0,8 because of peripheral localization of the graft.

No recurrent infection and corneal allograft rejection occurred during the follow-up period of 1-8 months after PKP. Secondary glaucoma was noted in one of the operated eyes (case 5) and glaucoma surgery was performed 4 months after PK. The intraocular pressure was controlled and corneal edema disappeared.

DISCUSSION

Urgent penetrating keratoplasty can preserve eye integrity and eradicate the infectious process in a large part of perforated bacterial corneal ulcers [1, 4]. Visual rehabilitation is often a secondary objective. After restoring of structural integrity of the globe, a subsequent smaller optical penetrating keratoplasty is an option in some of the eyes with graft rejection [1, 2, 3, 6].

Adapted antimicrobial treatment reduces graft reinfection and steroid treatment reduces the frequency of some complications, especially graft rejection [2, 5].

If PK were performed for a traumatic corneal perforation, grafts had a better chance to remain clear if surgery could be delayed. Early intervention is recommended in case of infectious corneal perforation since

the risk of endophthalmitis and the need for a larger diameter graft may be avoided [1, 10].

We found that anatomical integrity was achieved in all eyes perforated from corneal disease. Therapeutic PK cured the disease in all keratitis cases. The clear grafts were obtained in 80% (4 eyes) and semi-transparent in 20% (1 eye). These results are consistent with the literature. Nurozler found clear grafts in 23 eyes (60.9%) perforated from corneal disease and 40.5% of them obtained a final visual acuity of 0.2 or better [11]. Gong reported 40% transparent grafts after PK in cases with suppurative corneal ulcer and vision restored to 0.05 or better in 15 cases (37.5%) [7].

In our study preoperative visual acuity in all patients was low – light perception only. Four eyes obtained a final visual acuity between 0.2 and 0.9, and it was unchanged compared to the preoperative status in 1 eye due to mature cataract and secondary glaucoma (case 5). Nobe obtained the same results, as 80% of the PK that were delayed 3 months following primary repair of corneal laceration, remained clear, and 50% of these patients had a visual acuity of 0,3 or better [8]. In contrast, some recent studies report a visual acuity of 0,5 or better in only 15% to 41% of clear re-grafts [10]. Visual outcome depends on various factors such as the causative agent, timing of surgery, degree of inflammation, type of donor material used, and size of the graft used [6, 7, 8].

The main causes for failure of grafts including recurrence of previous infection and secondary glaucoma are also the leading causes of failure of repeat grafts [3,5]. Corneal neovascularisation is an independent risk factor that can jeopardize the outcome of a successfully performed keratoplasty by causing episodes of graft rejection.

Ocular surface problem was another cause of failure of primary graft. However, some ocular surface problems persisted in some eyes resulting in mild haze and hence remained the leading cause for suboptimal best corrected visual acuity in these re-grafts in spite of reasonably good graft clarity.

It is very important to identify and remove any potential risk factors that would have made cornea susceptible to development of keratitis, including wearing contact lenses, trauma, aqueous tear deficiencies, recent corneal disease, structural alteration or malposition of the eyelids, immunologic diseases and other [1,2].

CONCLUSIONS

Our results confirm that therapeutic penetrating keratoplasty for keratitis, especially in corneal perforation, is successful in restoring anatomic integrity and visual rehabilitation in most eyes. Without therapeutic surgery, these eyes would have been lost [1].

REFERENCE:

1. Murillo-Lopez F.: Keratitis, Bacterial. Emedicine, April 18, 2006
2. Bower K. S., Kowalski R. P., Gordon YJ: Fluoroquinolones in the treatment of bacterial keratitis. *Am J Ophthalmol* 1996; 121(6): 712-5
3. Sukhija J., Jain A. K.: Outcome of therapeutic penetrating keratoplasty in infectious keratitis. *Ophthalmic Surg Lasers Imaging*. 2005;36(4):303-9.
4. Hirst L. W., Smiddy W. E., Stark W. J.: Corneal perforations. Changing methods of treatment, 1960-1980. *Ophthalmology* 1982; 89(6): 630-5
5. Boujemaa C., Souissi K., Daghfous F., Marrakchi S., Jeddi A., Ayed S.: Urgent penetrating keratoplasty in perforated infectious corneal ulcers. *J Fr Ophtalmol*. 2005; 28(3):267-72.
6. Sony P., Sharma N., Vajpayee R. B., Ray M.: Therapeutic keratoplasty for infectious keratitis: a review of the literature. *CLAO J*. 2002; 28(3): 111-8.
7. Gong X.M., Chen J. Q., Feng C. M.: Penetrating keratoplasty in the treatment of corneal perforation. *Zhonghua Yan Ke Za Zhi*. 1994;30(1):8-10.
8. Nobe J. R., Moura B. T., Robin J. B., Smith R. E.: Results of penetrating keratoplasty for the treatment of corneal perforations. *Doheny Eye Institute, Los Angeles, CA 90033*. 1990;108 (7):
9. Jones D. B. Decision-making in the management of microbial keratitis. *Ophthalmology*. 1981;88:814-820
10. Cristol S. M., Alfonso E. C., Guildford J. H., Roussel T. J., Culbertson WW. Results of large penetrating keratoplasty in microbial keratitis. *Cornea*. 1996;15(6):571-6.
11. Nurozler A. B., Salvarli S., Budak K., Onat M., Duman S.. Results of therapeutic penetrating keratoplasty. *Jpn J Ophthalmol*. 2004;48(4):368-71.

Address for correspondence:

Chavdar Balabanov, MD, PhD
Eye clinic, UMBAL Dr George Stranski - II-nd Clinical Base,
91, Gen. Vladimir Vazov Str., 5800 Pleven, Bulgaria
E-mail: oftal@mail.bg