

## PRIMARY RENAL ECHINOCOCCOSIS- EXPERIENCE WITH 14 CASES

Krasimira Kalinova, Nicolai Usunov  
University Hospital Stara Zagora, Bulgaria

### ABSTRACT

Cystic hydatid disease may be found in any organ, although involvement of the urinary tract is relatively uncommon. Preoperative diagnosis of renal hydatid disease is difficult even in an endemic zone. A short review of the literature regarding diagnosis and management of renal echinococcosis is also presented. The treatment of hydatid cyst of the kidney is surgical. Renal-sparing surgery, cystectomy plus pericystectomy, is possible in most cases (75%). Nephrectomy (25% of cases) must be reserved for destroyed kidneys resulting from aged cysts opening into the excretory cavities and complicated by renal infection. Whether conservative or radical, the first surgery performed is cystectomy, with germinate membrane removal after controlled evacuation and opening of the cyst, making the subsequent steps of surgery easier.

Hydatid disease is endemic in several Mediterranean countries, posing an important health problem for these countries. The hydatid cyst is characterized by cystic lesions with clear boundaries, which can be observed in all part of the body.

A renal hydatid cyst is a benign parasitic infestation caused by larval growth of the cestode *Echinococcus granulosus* and is relatively uncommon compared to liver and lung localizations. Kidney involvement represents 4% of confirmed cases of hydatid disease.

### MATERIAL AND METHODS

A retrospective 17 years review of 14 renal hydatid cysts, calls treated and confirmed by pathology, is analyzed. Mean age was 25 years (between 15 and 65 years); eight men and six women. Clinical symptoms presentation, imaging modalities - US, CT, intravenous pyelography, serologic findings, type of surgery, and result were recorded for each case.

### RESULTS

We reviewed the clinical findings of a personal series of renal hydatidosis with emphasis on diagnostic and therapeutic issues. Clinical, radiologic and laboratory data are analyzed. The cyst was located at the upper pole - 35% or the lower - 30 %; 35% was mediorenal. The cyst was

frequently solitary - 85%; sometimes multifocalis - 15% and never a both.

### CLINICAL SIGNS

Renal hydatid cysts can remain asymptomatic many years a then be discovered incidentally. The main clinical symptom was lumbar pain-65% and a lumbar or abdominal mass-35%.

Digestive symptoms include subcostal pain, abdominal distention, and vomiting in 15% in our cases. Hematuria, provoked by calyx fissure, was sometimes the presenting symptom. In 50 % of the cases has hydatiduria. There was no specific or pathognomonic laboratory test for renal hydatidosis except hydatiduria, which is observed in 10 % in the cases.

### IMAGING STUDIES

Radiologic exploration has had an interesting evolution, with the appearance of ultrasonography and computed tomography. Diagnostic accuracy has been greater since the availability of ultrasonography and immunologic studies. Five cases were incidentally discovered on plain radiography or ultrasonography.

Hydatid cysts are classified according to the ultrasonographic appearances described by Gharbi. The univesicular cyst in children most frequent (9 cases). The univesicular cyst -type II with floating membrane is pathognomonic of the hydatid cyst and was observed in three cases in our series. Multivesicular cyst, type (III) in our series is two. Ultrasonography revealed a well-defined, hypoechoic mass with multiple hyperechoic septation. (Fig. 1. and Fig. 2.) IVP, sometimes retrograde pyelography were used in the past.

**Intravenous urography** with conventional tomography performed after 15 minutes after contrast material injection demonstrated normal excretion in the right kidney but a delayed nephrogram in the left kidney.

Intravenous urogram shows a large, radiolucent tumor in the upper pole of the left kidney with faint curvilinear calcification superiorly. The caliceal system is not seen. (Fig. 3.)

CT usually performed after US, where the appearance of the US scan was not typical of hydatid disease and the nature of the cystic tumor was uncertain.

**CT scan** demonstrates a large; thick-walled cystic mass anteriorly in the upper pole of the left kidney. The mass consists of multiple small cystic lesions with typical peripheral location. (Fig. 4.)

**Magnetic resonance (MRI)** imaging was performed to confirm this hypothesis and visualize the lesion in different planes. The small peripheral cysts were clearly hypointense relative to the central component.

**Serologic Studies used:** Serologic tests: Immunofluorescence; Indirect hemagglutination and Enzyme-linked immunosorbent assay (ELISA). The last test is high specific to hydatid disease - 98%.

**Treatment** The treatment of hydatid cyst of the kidney is surgical and lumbar approach was the usually. In 8 cases were used abdominal transperitoneal approaches.

- Cystectomy - in 6
- Treatment of the pericyst – in the two
- Total nephrectomy in 6 cases - the tumor in this case was quite large and residual kidney function was very poor. (Fig. 5.) - Huge white cyst (13\8 cm) containing radiolucent fluid and daughter cysts of varying size.

The complications observed were related to conservative surgery. Infection of the remnant cavity appeared on two cases. 60% patients were monitored 5 years and more. There one recurrences.

## DISCUSSION AND CONCLUSION

Isolated primary renal hydatidosis is extremely rare. Correct preoperative diagnosis is not always easy. Renal hydatid disease mimicked other diseases. The combination of clinical history, imaging studies, and serological and urine investigation yielded a reliable pretreatment diagnosis in only 50% of cases and a presumptive diagnosis in 71% (1,2). Ultrasonography, CT and serologic investigations have facilitated the diagnosis of renal hydatid cysts. US is the most appropriate method for the differential diagnosis of a renal cystic tumor and very sensitive - 95% for diagnosis. It is safe and inexpensive. CT should be reserved for equivocal cases (3).

The treatment of hydatid cyst of the kidney is surgical. Renal-sparing surgery, cystectomy plus pericystectomy, is possible in most cases (75%).

Whether conservative or radical, the first surgery performed is cystectomy, with germinate membrane removal after controlled evacuation and opening of the cyst, making the subsequent of surgery easier (4).

The cyst is then punctured and aspirated before filled with hydrogen peroxide or 10% Povidon-jodine for 5 minutes. This maneuver reduced the internal pressure of the cyst, sterilizes the cystic content, and allows the second step, which is controlled opening of the cyst and its controlled evacuation with a spoon.

Cystectomy plus partial pericystectomy is the technique most often used and it can be performed

regardless of the size of the cyst. After cystectomy, the cavity is covered with sponges soaked with 10 % Povidone-jodine.

Partial pericystectomy is indicated when the pericyst is supple or if bleeding occurs while the dissection is carried out, followed by Capitonnage, re-approximation of the pericyst or marsupialisation. Total pericystectomy is indicated when the pericyst is dense or calcified.

The resection of the prominent dome remains the standard option as it allows preservation of the kidney (5). Nephrectomy (25%) must be reserved for destroyed kidneys resulting from aged cysts opening into the excretory cavities, and complicated by renal infection.

The percutaneous management, which includes puncture, aspiration, injection, and reaspiration, can be performed in much selected cases. Surgical management consists of various options (6). Renal sparing surgery by way of partial excision is possible in 75% cases and is the most adapted treatment whenever possible. Partial excision should be preceded by the injection of scolicidal agents into the cyst which include 20% hypertonic saline, 10% Povidon-jodine, 3% H<sub>2</sub>O<sub>2</sub>. Patient has to be operated under the cover of antihistaminics and steroids for the fear of anaphylaxis if cyst rupture occurs during surgery. No intervention is needed when the cyst walls are calcified. Patient can be started on a course of oral Albendazole after surgery.

**Conclusion:** Conservative management and long term follow up are proposed for the non-active or mebendazole-responsive patients. For the non-respondents or the cases with kidney destruction, surgery is the only hope for cure.

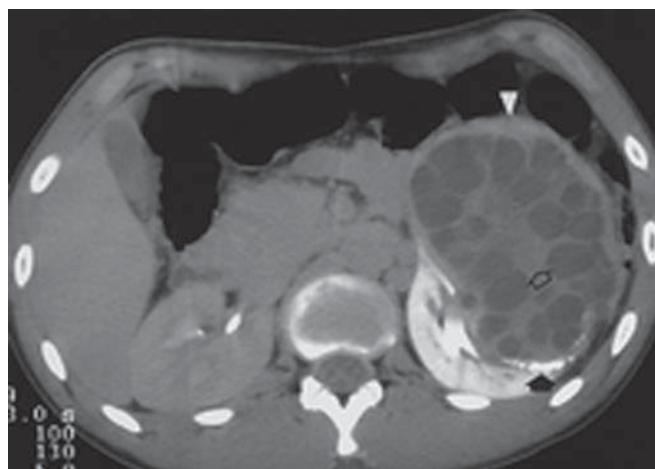


Fig. 1.

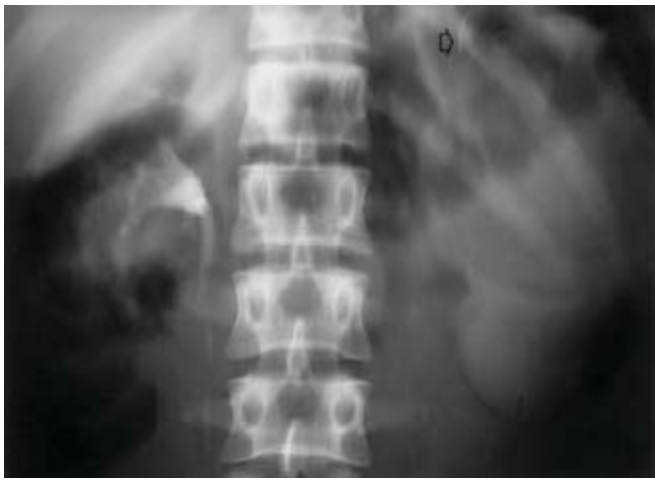

Fig. 2.

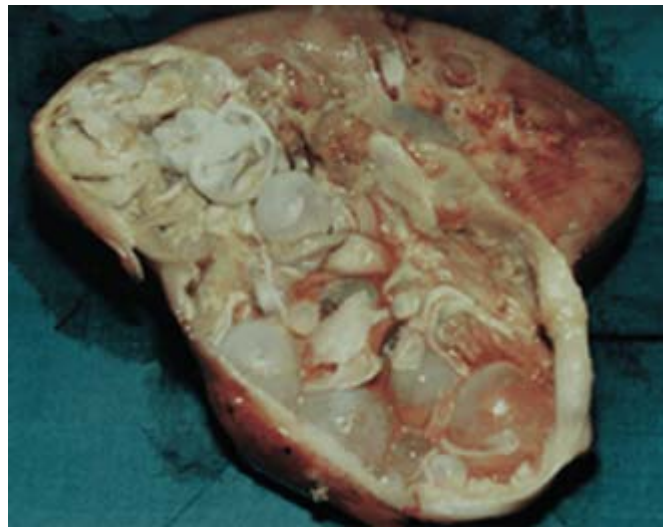

Fig. 3.

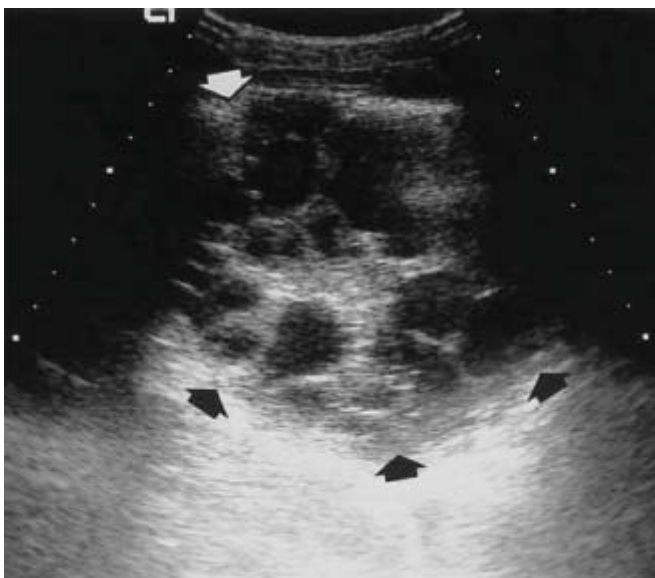

Fig. 4.



Fig. 5.

## REFERENCES

1. Ameer A, Lezrek M, Boumdin H, et al. Hydatid cyst of the kidney based on a series of 34 cases. *Prog Urol* 2002; 12 (3): 409-14.
2. Gogus C, Safak M, Baltaci S, Turkolmez K. Isolated renal hydatidosis: experience with 20 cases. *J Urol* 2003; 169 (1): 186-9.
3. Vargas-Serrano B., Ferreiro-Arguelles C. Imaging findings in renal hydatid disease Rodriguez-Romero R, Marcos del Rio N. *Eur Radiol* 1997; 7(4): 548-51.
4. Angulo JC, Sanchez-Chapado M, Diego A, et al. Renal echinococcosis: clinical study of 34 cases *J Urol* 1997; 157 (3): 787.
5. Sir Alfred Cushieri, R J C Steele, AN R Moosa, Treatment of Hydatid Cyst, *Essential Surgical Practice*, 4th ed. Arnold Publishers; 350.
6. Akhan O, Ustunsoz B, Somuncu I, et al. Percutaneous renal hydatid cyst treatment: long-term results. *Abdom Imaging* 1998; 23(2): 209-13.

Corresponding author:  
 Dr Krasimira Kalinova  
 E-mail: krasimirakalinova@abv.bg