

## EPIDERMOLYSIS BULLOSA SIMPLEX DOWLING-MEARA - A CASE REPORT

Ivelina Yordanova<sup>1</sup>, Snejina Vassileva<sup>2</sup>, Zdravka Demerjjeva<sup>2</sup>, Dimitar Gospodinov<sup>1</sup>, Nikolai Tsankov<sup>2</sup>

<sup>1</sup>*Department of Dermatology and Venereology, Medical University – Pleven, Bulgaria*

<sup>2</sup>*Department of Dermatology and Venereology, Medical University – Sofia, Bulgaria*

### ABSTRACT

A case with Epidermolysis bullosa simplex Dowling-Meara is presented. It concerns a 20 days breast-fed girl with severe blistering and erosions on the skin formed at birth after minor mechanical trauma. There are no other affected relatives. A medical examination showed normal somatic and visceral status. There were multiple herpetiform grouped bullous and erosive lesions on the face, trunk, upper and lower limbs, palms and soles. The mucous membranes were not affected. There was also a marked nail dystrophy on the fingers and toenails. The electron microscopic examination revealed cytolysis of the basal keratinocytes with clumping of the perinuclear tonofilaments in the lesional skin. Because of the clinical features and the results of the electron microscopic examination of the skin the case here reported should be considered as an Epidermolysis bullosa simplex Dowling-Meara. The child is followed up to the age of three. The course of the disease was benign with a decreased formation of blisters and erosions. The marked nail dystrophy was persistent. There was palmar and plantar hyperkeratosis. The child's growth, neural and psychic development was normal. The early diagnosis of the bullous epidermolysis is helpful in the prognostic assessment of the disease and in the medical and genetic advice for the parents.

**Key words:** Epidermolysis bullosa simplex Dowling-Meara, tonofilament clumps, electron microscopy.

### INTRODUCTION:

Epidermolysis bullosa simplex (EBS) is a group of hereditary bullous diseases characterized by intraepidermal blistering due to mild mechanical traumas (3). Patients are presented with widely varying severity and are classified in three main subtypes: EBS Weber-Cockayne, EBS Kobner and EBS Dowling-Meara, on the basis of the severity and distribution of the blisters, the age of onset, and the ultrastructural investigation of the epidermis and basement membrane zone. The three major clinical subtypes are all caused by mutations in either the keratin 5 (KRT5) or keratin 14 (KRT14) gene (6, 7). The prevalence of the EBS has been assessed in several countries (11, 12). The most detailed

investigation has been made in Scotland, where the point prevalence of EBS has been calculated as 28, 6 per million, with the Dowling-Meara subtype accounting for 0, 6 per million (11). The Dowling-Meara subtype of EBS is a rare severe blistering disease inherited in an autosomal-dominant fashion. There is a great range of severity in the various cases. Blistering may be exceptionally severe during the neonatal period and frequently occur on the face, trunk and limbs and tend to be disposed in herpetiform groups. In the most severe cases, blistering may appear spontaneously. Other physical signs include varying degrees of intra-oral blistering, nail dystrophy, minor scarring, palmo-plantar keratoderma, a lack of seasonal variation and improvement during later childhood (3). A case with Epidermolysis bullosa simplex Dowling-Meara is presented.

### Case report:

A 20 days old breast-fed girl was born from first normal pregnancy, with body weight 2700 g and height 47 cm. The disease started at birth with severe blistering and erosions on the face, trunk and extremities formed after minor mechanical traumas. The blisters also appeared spontaneously. They ruptured and formed extensive superficial erosions. The latter healed in the centre with recurrent blistering at the margins of these areas within a week. There were no other affected relatives. The child was hospitalized in a damaged skin condition.

A medical examination showed normal somatic and visceral status, muscle tone and reflexes with exception of the spontaneous and provoked clonus of the extremities. Dermatological examination revealed multiple herpetiform grouped bullous and erosive lesions, slight scars and milia on the face, trunk, upper and lower limbs (fig.1). There were hemorrhagic blisters on the palms and soles. The mucous membranes were not affected. There was also a marked nail dystrophy on the fingers and toenails. The routine blood count, biochemistry and urine analysis were within the normal limits with the exception of hypoproteinaemia (total protein - 58 g/l; normal values: 60-84 g/l), calcium deficiency (Ca - 1,83 mmol/l, normal values: 2,1 – 2,6 mmol/l) and phosphorus

excess in the serum (P - 2,76 mmol/l, normal values 1,0-1,5 mmol/l). The culture from skin lesions grows *Enterococcus faecalis*. The haemoculture was negative.

The routine light microscopy examination of the lesional skin (H&E) showed an intraepidermal separation. The immunohistochemical examination of the skin with monoclonal antibody against type IV collagen revealed the basement membrane marking on the floor of the blister cavity. The electron microscopy examination (electron microscope Hitachi-H 500 Japan) of the skin sample obtained from the edge of the fresh blister revealed cytolysis of the basal keratinocytes with clumping of the perinuclear tonofilaments (fig.2). Hemidesmosomes and anchoring fibrils were normal in appearance. The genealogical analysis was classified that case as sporadic without clear pedigree criteria for a single gene (Mendelian) mode of inheritance (fig. 3). The karyotype of the girl was normal. Because of the clinical features and the results of the electron microscopic and immunohistochemical examination of the skin a diagnosis of epidermolysis bullosa simplex Dowling-Meara was accepted.

After 10 days of systemic antibacterial treatment with Ampicillin/ Sulbactam sodium (2 x 150 mg i.v. / daily) and parenteral intravenous therapy with water-salt solutions, a significant improvement was observed. The skin lesions were treated with topical antiseptic, antibacterial agents and nonadherent dressings. The girl was fed with adapted nutritional milk formula.

The child is followed up to the age of three. The course of the disease was benign with a decreased formation of blisters and erosions on the skin surface. There was prominent palmar and plantar hyperkeratosis (fig.4). The marked nail dystrophy was persistent with a tendency to form trumpet nail deformity. The child's growth, neural and psychic developments were normal.

#### DISCUSSION:

The Dowling-Meara variant of epidermolysis bullosa simplex is characterized clinically by exceptionally severe blistering with an onset in early infancy after minor mechanical trauma. In the most severe cases, blistering may appear quite spontaneously, particularly in hot environment. Blisters frequently occur in other areas of the face, trunk and extremities and are disposed in herpetiform groups with annular or arcuate erythematous borders (2, 9). In the cases with EBS Dowling-Meara the blisters are more often hemorrhagic than in other forms of EBS. Milia and minor scarring may be a transient feature after the blisters have healed (3). In the patients with EBS Dowling-Meara the hands and feet are the sites of predilection and the blisters at these sites are similar to those seen in other forms of EBS. However it is particularly characteristic for blistering on the palms and soles to be succeeded by focal keratoderma, usually to a lesser degree (10). On occasions this keratoderma may be very prominent and be associated with flexion deformity and

a loss of function (3). A rather characteristic thickening of the nails is also common in Dowling-Meara EBS (14). Even in the neonatal period involvement of the hands and feet is prominent and it is already associated with nail thickening – this combination can be diagnostically helpful. Some cases during the neonatal period may be presented with more widespread erosive skin and mucous membranes lesions. Severely affected neonates have extreme oropharyngeal blistering with potentially serious interference with feeding (3). Hoarseness of the voice is quite often present particularly in the more severely affected cases; a weak cry may be noticeable in the neonate period. Death in the neonatal period is probably not infrequent and many of these severe cases were previously probably thought to have lethal Junctional Epidermolysis Bullosa or recessive Dystrophic Epidermolysis Bullosa (7). It is difficult to distinguish the Dowling-Meara EBS from other forms of epidermolysis bullosa in the neonatal period. Immunohistochemistry and electron microscopy usually allow differentiation (4, 5). The differential diagnosis includes also incontinentia pigmenti, bullous ichthyosiform erythrodermia, staphylococcal scalded skin syndrome, neonatal or congenital varicella, neonatal pemphigus, pemphigoid, aplasia cutis, pachyonychia congenita. Microscopically The Dowling-Meara variant of EBS is characterized by cytolysis of the basal cells. Ultrastructurally it is characterized by clumping of the keratin tonofilaments within areas of incipient blistering. (1). Discrete circumscribed clumps of keratin filaments in the basal keratinocytes are pathognomonic. There are different forms of tonofilament clumps. In some cases there was round clumping of tonofilaments, as in our case, in other a whisk-type clumping of tonofilaments. (1, 2). Electron microscopy is the best means of demonstrating the characteristic cytoskeletal disorder and confirming the diagnosis(7). The skin fragility is due to genetic defects of keratin 5 and keratin 14 which are intermediate filament proteins expressed in the cytoskeleton of the basal keratinocytes (13). The mutated keratins 5 and 14 clump together, thus causing clefts in the keratinocytes. Molecular biologists have detected various mutations in KRT5 or KRT14 gene in EBS Dowling-Meara patients. (15). The affected individuals may have inherited the mutated gene from an affected parent (autosomal-dominant mode of inheritance) or have the mutated gene as the result of a de novo gene mutation (80 % of the sporadic cases) (7). We consider our case a de novo gene mutation since there is no family history.

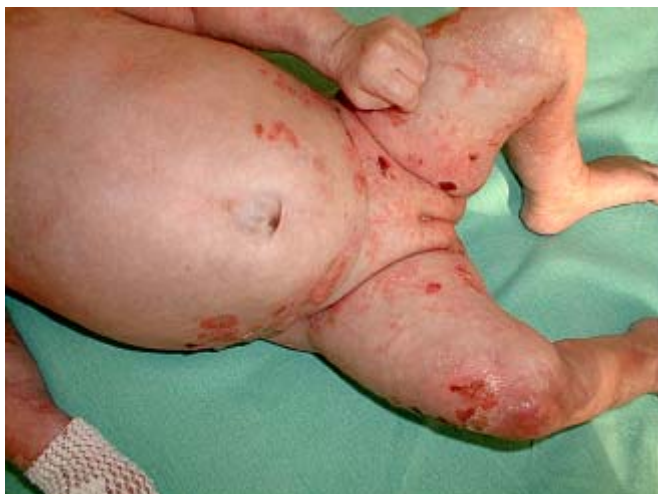Although the disease can be severe in early infancy the blistering tendency may improve with age, just like in our case (8, 10). However, some adults remain substantially disabled by Dowling-Meara EBS throughout their lives as a result of persisting blistering of the hands and feet and palmar and plantar keratoderma (3).

No treatment of any of the groups of EBS is available so far. It is only symptomatic and the primary aim is to protect the skin and stop blister formation. Fresh blisters should be

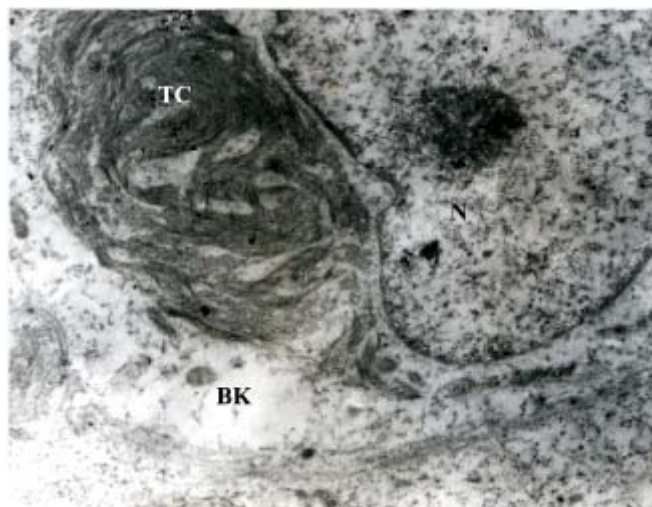
drained after puncturing them with a sterile disposable needle and then dressed with nonadherent dressings. Topical antiseptic and antimicrobial agents should be used to protect from secondary bacterial infection. It is very important to avoid the use of tight dressings and footwear, avoidance of high environmental temperatures, nasogastric feeding in the

cases of severely affected with Dowling-Meara neonates (3).

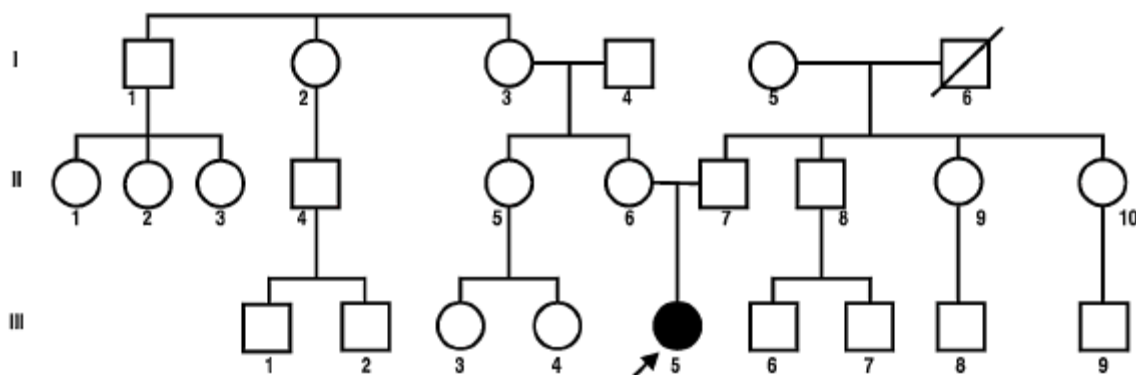
In conclusion the EBS Dowling-Meara case we described above demonstrates severe blistering at birth and relative benign course of the disease with age. The correct diagnosis is helpful in the prognostic assessment of the disease and in the medical and genetic advice for the parents.



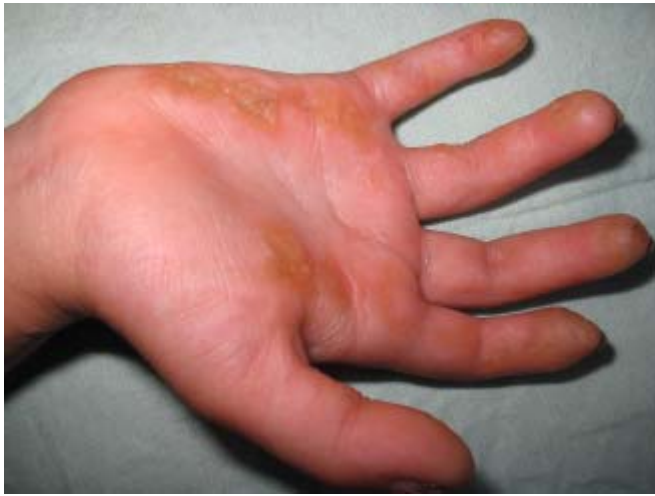**Fig. 1.** Multiple herpetiform grouped bullous and erosive lesions on the trunk and lower limbs and slight atrophic scars.



**Fig. 2.** Electron microscopy of the lesional skin (24 000 x): a basal keratinocyte with tonofilaments clumping perinuclearly: BK – basal keratinocyte, TC - tonofilaments clumps, N - nucleus.



**Fig. 3.** Pedigree of the affected family. The proband III-5 is a sporadic case. Filled symbol indicates proband affected with the disease (marked with an arrow); open symbols - unaffected family members.



**Fig. 4.** Patchy palmar hyperkeratosis at the age of three.

#### REFERENCES:

1. Anton-Lamprecht I. - Keratin clumping in Epidermolysis bullosa, Dowling-Meara type. *Br. J. Dermatol.* 134, 184-185, 1996.
2. Anton-Lamprecht I, Schnyder U.W. - Epidermolysis bullosa herpetiformis Dowling-Meara. Report of a case and pathomorphogenesis. *Dermatologica.* 164(4), 221-235, 1982.
3. Atherton D.J. - Epidermolysis bullosa. In *Textbook of Pediatric Dermatology*. ed. by Harper J, Oranje A., Prose N. Blackwell Science, Berlin, Germany, 2000 Vol.2: pp.1075-1099.
4. Bergman R. - Immunohistopathologic diagnosis of Epidermolysis bullosa. *Am. J. Dermatopathol.* 21(2), 185-192, 1999.
5. Bolte C., Gonzales S. - Rapid diagnosis of major variants of congenital epidermolysis bullosa using a monoclonal antibody against collagen type IV. *Am. J. Dermatopathol.* 17(6), 580-583, 1995.
6. Cummins R.E., Klingberg S., Wesley J. et Al. - Keratin 14 point mutations at codon 119 of helix 1A resulting in different epidermolysis bullosa simplex phenotypes. *J. Invest. Dermatol.* 117, 1103-1107, 2001.
7. Fine J-D, Eady R.A.J., Bauer E.A. et Al. - Revised classification system for inherited epidermolysis bullosa: Report of the Second International Consensus Meeting on diagnosis and classification of epidermolysis bullosa. *J. Am. Acad. Dermatol.* 42, 1051 – 1066, 2000.
8. Frangu M., Gedde-Dahl T. Jr., Verder H. - Epidermolysis bullosa simplex Dowling-Meara. *Ugeskr. Laeger.* 168(48), 4222-24, 2006.
9. Furumura M., Imayama S., Hori Y. - Three neonatal cases of epidermolysis bullosa herpetiformis (Dowling-Meara type) with severe erosive skin lesions. *J. Am. Acad. Dermatol.* 28, 859-861, 1993.
10. Hacham-Zadeh S., Rappersberger K., Livshin R., Konrad K. - Epidermolysis bullosa herpetiformis Dowling-Meara in a large family. *J. Am. Acad. Dermatol.* 18, 702-706, 1988.
11. Horn H., Priestley G., Eady R., Tidman M. - The prevalence of epidermolysis bullosa in Scotland. *Br. J. Dermatol.* 136, 560-564, 1997.
12. Inaba Y., Kitamura K., Ogawa H. et Al. - A study on the prevalence of epidermolysis bullosa in Japan. *Nippon. Hifuka. Gakkai. Zashi.* 99, 1021-1026, 1989.
13. Ishida-Yamamoto A., McGrath J.A., Chapman S.J. et Al. - Epidermolysis bullosa simplex (Dowling-Meara type) is a genetic disease characterized by an abnormal keratin-filament network involving keratins K5 and K14. *J. Invest. Dermatol.* 97(6), 959-968, 1991.
14. Jacobzone C., Conan-Charlet V., Plantin-Eon I. et Al. - Trumpet nail deformity during the course of Dowling-Meara type epidermolysis bullosa simplex. A report of two cases. *Ann. Dermatol. Venereol.* 129, 424-427, 2002.
15. Kemp M. W., Klingberg S., Lloyd L. et Al. - A novel deletion mutation in keratin 5 causing the removal of 5 amino acids and elevated mutant mRNA levels in Dowling-Meara epidermolysis bullosa simplex. *J. Invest. Dermatol.* 124, 1083-1085, 2005.

*The case was presented at the 14<sup>th</sup> Congress of the European Academy of Dermatology and Venereology – London, October 14 - 16, 2005.*

#### Address for correspondence:

Ivelina Yordanova, MD. PhD  
 Department of Dermatology and Venereology, Medical University – Pleven,  
 91, Gen. Vladimir Vasov str., 5800 Pleven, Bulgaria  
 Tel.: +359 (64) 688 758; E-mail: ivelina\_yordanova@abv.bg