



LATE NEUROSYPHILIS: TRENDS AND CHALLENGES

Ivan Dimitrov¹, Ara Kaprelyan², Milena Gentcheva³, Borislav Ivanov⁴, Radoslav Georgiev⁵, Tony Avramov⁶, Yavor Entchev⁶, Nadezhda Deleva²

1) Department of Nursing, Sliven Affiliate, Medical University - Varna, Bulgaria

2) Department of Neurology, Medical University - Varna, Bulgaria

3) Department of Dermatology and Venereology, Medical University - Varna, Bulgaria

4) Department of Clinical Medical Sciences, Faculty of Dental Medicine, Medical University - Varna, Bulgaria

5) Department of Imaging Diagnostics and Radiotherapy, Medical University - Varna, Bulgaria

6) Department of Neurosurgery and Otolaryngology, Medical University - Varna, Bulgaria

ABSTRACT

Background: Syphilis is not only a disease of historical importance. It has been recognized that nowadays, in the era of AIDS, it still remains a serious challenge. For the last two decades there has been a resumption of neurosyphilis cases. This has revived the interest in the diagnostic and therapeutic challenges that the disease presents to clinical practice and to healthcare systems.

Material/Methods: We present the overall picture of newly registered cases of syphilis in Varna municipality between 2009 and 2013, and report a case of neurosyphilis diagnosed at the first clinic of neurological diseases of St. Marina University Hospital during this period.

Results: For the 5-year period, newly registered cases of syphilis in Varna have shown a tendency towards a decrease. Patients were typically in the early stages of the disease, primary and secondary. Late manifestations dropped from 29 in 2009 to 0 in 2010, but increased again to 15 in 2013. Only 1 case of neurosyphilis was registered during the 5-year period, in 2013.

Conclusions: Neurological syndromes observed in cases of late neurosyphilis, presenting in different clinical forms, require a broad spectrum of differential diagnoses. Attention in everyday clinical practice should be focused on these cases which, though rare, are of high medical and social importance. Clinical cases of late neurosyphilis are often atypical and the early consideration of serologic tests or even biopsy may be of critical importance.

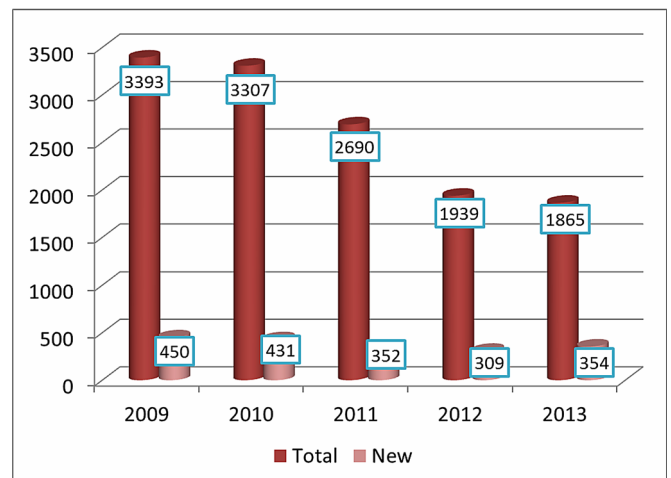
Keywords: Biopsy, Neurosyphilis, Serologic tests, Syphilis

INTRODUCTION

Syphilis has been recognized not only as a disease of historical importance, as even in the era of AIDS it remains a serious challenge. Epidemiological data from population-based studies are though insufficient [1]. According to data published by the National Statistical Institute [2] the number of registered cases of syphilis in Bulgaria has decreased from

3393 to 1865 between the years 2009 and 2013. The yearly registration of new cases has followed the same trend between 2009 and 2012, decreasing from 450 to 309, but in 2013 it has marked an increase to 354 cases (Fig.1).

Fig. 1. Registered Cases of Syphilis in Bulgaria (2009-2013)



A recent opinion states that the epidemiology of neurosyphilis has largely paralleled that of syphilis in general [3]. On the other hand, reported cases of late neurosyphilis nowadays mark a worldwide decrease while incidence of syphilis in general has been known to increase since the year 2000, mostly due to ineffective prevention. The higher incidence of syphilis requires increased attention towards the diagnostic process and its specific difficulties.

Late forms of neurosyphilis are well known and extensively studied in the literature, but they are likely to lack some typical presenting features, and thus become a diagnostic challenge in neurological practice [4]. Therefore, together with neuroimaging, broader use of serology is recommended, though it may not be invariably accurate [3, 5]. Non-specific tests, VDRL (Venereal Disease Research Labo-

ratory test), and RPR (Rapid Plasma Reagin test) are used for screening and to monitor the activity of the disease (and the success of treatment, respectively) but they can be false positive. Specific treponemal tests, FTA-ABS (Fluorescent Treponemal Antibody absorption test) and MHA-TP/TPHA (Microhemmagglutination Assay for antibodies to *T. pallidum*) are standardized and highly specific. They are capable of confirming present or past infection and may be false positive only in rare cases. The most sensitive, but also most difficult test to perform is *T. pallidum* immobilization (TPI) which is mostly used in research. The polymerase chain reaction (PCR) test is expensive and does not outperform the other tests in terms of confirming neurosyphilis. The cerebrospinal fluid VDRL test is considered highly specific, especially in meningovascular syphilis and progressive paralysis [6].

MATERIAL & METHODS

We present the overall picture of newly registered cases of syphilis in Varna municipality for five years, between 2009 and 2013. The study is retrospective. The data is based on the documentation kept at the Sexually Transmitted Diseases Centre (STDC) in Varna: dispensary cards of patients under follow-up. We also describe the single registered case of late neurosyphilis, diagnosed at the First clinic of neurological diseases of St. Marina University Hospital during this period.

RESULTS

For the 5-year period between 2009 and 2013, newly registered cases of syphilis at the STDC in Varna have shown a tendency towards a decrease. The number was 33 in 2013, compared to 80 in 2009. The trend was varying though, with slight peaks in 2011 and 2013 (Table 1). Males were predominating over females, accounting for about 70% of cases. Newly diagnosed patients were typically in the early stages of the disease, primary and secondary. The number of cases in second stage, latent form, was significantly greater. Late manifestations dropped from 29 in 2009 to 0 in 2010, remained up to 2012, but increased again to 15 in 2013. Cases of congenital syphilis decreased. Only 1 case of neurosyphilis was registered during the 5-year period, in 2013.

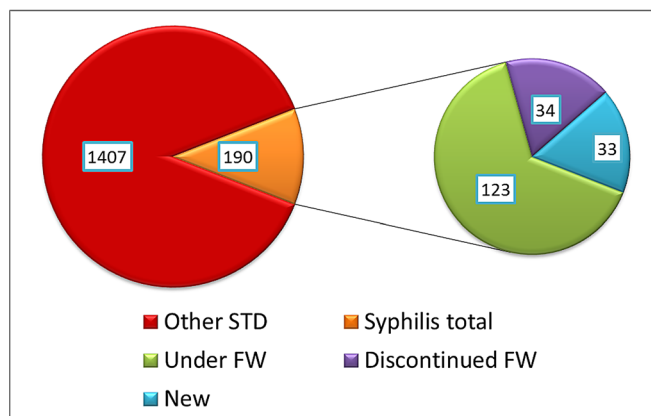
Table 1. New cases of early, late and congenital syphilis registered at the STDC in Varna (n) by year

	2009	2010	2011	2012	2013	Total
Early syphilis	41	29	53	23	16	162
Late syphilis	29	0	0	0	15	44
Congenital syphilis	10	4	1	1	2	18
Total	80	33	54	24	33	224

During the year 2013, 1407 patients were consulted at the STDC for Varna municipality and the North-eastern region of Bulgaria, 190 having syphilis (Fig.2). Of these, 33 were newly registered cases in 2013, while 123 had been diagnosed in previous years and remained under observa-

tion and regular serological tests. Follow-up of 34 patients with a definite diagnosis of syphilis who completed treatment in 2013 was discontinued.

Fig. 2. Patients Consulted at the STDC in Varna in 2013 (n)



FW – follow-up

CASE REPORT

We have diagnosed a rare hyperplastic spinal syphilitic meningitis with atypical presentation: subacute development of spinal cord compression leading to a delayed hospitalization which was only performed after impairment of bladder function and walking had developed. Neurological examination revealed a severe spastic paraparesis and hyperreflexia, more pronounced on the right, bilateral Babinski and Chaddock signs, Rossolimo sign on the left and Hoffmann/Troemner signs on the right. The patient needed bilateral support in order to walk. Position sense was impaired in all joints of the lower extremities. Hypoesthesia below the level of Th3-5 was found. Pressure at Th1-2 and Th4-5 Valleix points was painful. Urinary retention and difficult defecation were reported.

Magnetic resonance imaging was carried out, showing nonspecific diffuse enlargement of dural sheets and narrowed spinal space with compression of the cord. Differential diagnosis was broad, including tuberculosis, neuroborreliosis, sarcoidosis, fungal infection, metastatic or idiopathic process.

In serum, antibodies against syphilis (ELISA) were positive, VDRL was negative, and TPHA was highly positive (4+). CMV, EBV and *B. burgdorferi* IgG antibodies were positive, but IgM were negative. HIV test was negative. Cerebrospinal fluid (CSF) assessment results were also in line with the diagnosis of neurosyphilis. ELISA for antibodies against syphilis was positive. *B. burgdorferi* and HSV1 IgG were positive, and IgM were negative. VZV and HIV antibodies were negative. Routine CSF assessment revealed WBCs 500/3, RBCs 3/3, glucose 2.1 mmol/l, protein 11.72 g/l, sediment: 91% mononuclear and 9% polymorphonuclear leukocytes. Microbiological cultures remained sterile. Treatment with ceftriaxone 2x2 g/day i.v. for 15 days was carried out. Urinary catheter was applied. Sur-

gical decompression of the spinal cord and roots was performed. Biopsy results were in line with the diagnosis: neurosyphilis, presenting as a hyperplastic spinal meningitis, causing compression of the spinal cord at the thoracic level and resulting in spastic paraparesis, bladder and bowel dysfunction. After treatment the general condition of the patient improved and bladder functions returned to normal. Improvement of paraparesis and gait was observed.

DISCUSSION

Unlike literature data, our findings demonstrate a decrease of the total number of newly registered cases of syphilis, these being predominantly in the early stages of the disease. As in other publications, male patients predominate. The number of cases at second stage, latent form, is significantly greater. At the same time the number of late manifestations with marked cutaneous symptoms increases. A study of cases of syphilis in a French hospital for a 10 year period showed that neurosyphilis was encountered in 50% of cases, and the number of positive serology results had an eightfold increase [5]. Another study in Italy demonstrated that among 138 patients, 60% had latent syphilis, 21% had secondary, 10% had neurosyphilis, and 9% had primary syphilis [7]. Male patients predominated significantly in both above-cited studies.

A strict screening program for pregnant women has been observed in order to assure early diagnosis of congenital forms, and the registered cases per year have decreased since 2009.

A large percentage of registered patients have been actively discovered, because of having had close contact with already diagnosed patients, though themselves being asymptomatic. They remain subject to treatment and periodic serological follow-up assessment.

The general picture of newly registered cases of patients with syphilis in Varna community for the last five years is important for estimating how the disease is spreading and for planning future activities. Despite the decreasing number of diseased persons, the appearance of new cases of neurosyphilis remains a potential danger, confirmed by the increasing number of individuals with other late manifestations. The single registered case of late neurosyphilis was diagnosed at the First clinic of neurological diseases of St. Marina University Hospital in Varna. It appears significant in several aspects by demonstrating the clinical polymorphism and atypical features of neurosyphilis, the need for detailed assessments, and the challenges that the interpretation of classical tests may impose. Notably in

atypical cases such as ours it is recommended to consider neurosyphilis early, to perform serological tests and sometimes even biopsy. Late stages of the disease represent a particular diagnostic, but also therapeutic challenge [8-11].

Neuropsychiatric, meningovascular and myelopathic forms of neurosyphilis are well known, but in daily clinical practice other, more frequent neurological disorders may dominate the clinical thinking during the diagnostic process. In our case these included intercostal neuralgia, tumors of the spinal cord, Wegener granulomatosis, cauda equina syndrome, disc herniation, spinal form of multiple sclerosis, spinal stroke, transverse myelitis, amyotrophic lateral sclerosis, poliomyelitis, syringomyelia, etc. Difficulties in interpreting serological tests should also be considered.

The present clinical case of neurosyphilis diagnosed at a late stage and presenting atypically, together with the data about the registered number and clinical forms of syphilis in Varna municipality, emphasizes the importance of screening for *T. pallidum* infection in neurological practice. As therapeutic results depend on the early diagnosis, precise neuroimaging and even biopsy can be crucial. A precise diagnosis followed by appropriate treatment should lead to satisfying results for the patient, but also for the society [12-14].

The attention of neurologists should be more focused on neurosyphilis. Even if it is a rare disease, it proves to be particularly important because of its clinical polymorphism, the broad differential diagnosis, the difficult interpretation of serological tests, and also because of its high medical and social importance.

CONCLUSIONS

Neurological syndromes observed in cases of late neurosyphilis, presenting in different clinical forms, require a broad spectrum of differential diagnoses. Attention in everyday clinical practice should be focused on these cases which, though rare, are of high medical and social importance. They are often atypical and the early consideration of serologic tests or even biopsy in some cases may be of critical importance. All therapeutic options should be used, including neurosurgical treatment, even in cases with severe impairment. A timely diagnosis would assure better results and disease outcome. At the same time this is an effective measure for reducing incidence and prevalence. The wider application of screening for *T. pallidum* infection in neurological practice would contribute to improving the control of syphilis.

Acknowledgments

No grants or funding were used for this study.

REFERENCES:

1. Ghanem KG. Review: Neurosyphilis: A historical perspective and review. *CNS Neurosci Ther.* 2010 Oct; 16(5):e157-168. [[PubMed](#)] [[CrossRef](#)]
2. National center for public health and analysis of the Ministry of health. *Healthcare 2014.* Sofia, 2015. [in Bulgarian]
3. Berger JR, Dean D. Neurosyphilis. *Handb Clin Neurol.* 2014; 121: 1461-1472. [[PubMed](#)] [[CrossRef](#)]
4. Dimitrov I, Avramov O, Kaprelyan A, Georgiev R, Enchev Y, Ivanov B, et al. A rare case of hypertrophic spinal luetic meningitis presenting as a transverse lesion of the spinal cord. *Balgarska neurologiya.* 2013 Dec; 14(3):162-167. [in Bulgarian]
5. Lefebvre M, Biron C, Guillouzoic A, Juvin ME, Masseur A, Néel A, et al. Syphilis in Nantes tertiary care hospital between 2000 and 2010: a case series of 36 hospitalized patients. *Rev Med Interne.* 2013 Sep; 34(9):522-527. [in French] [[PubMed](#)] [[CrossRef](#)]
6. Deleva N. Neurolyues. In: Neurology. Milanov I, edit. *Sofia:Meditsina & fizkultura,* 2012, p568-574. [in Bulgarian]
7. Malincarne L, Angeli G, Francisci D, Baldelli F, Pasticci MB. [Trend of syphilis among patients at the Infectious Diseases Clinic of Perugia, Italy: a six-year observational retrospective study.] [in Italian] *Infez Med.* 2013 Mar;21(1): 14-20. [[PubMed](#)]
8. Costiniuk CT, MacPherson PA. Neurocognitive and psychiatric changes as the initial presentation of neurosyphilis. *CMAJ.* 2013 Apr;185(6):499-503. [[PubMed](#)] [[CrossRef](#)]
9. Obi K, Tsuchiya K, Anno M, Ohta S, Nakamura R, Akiyama H. [Autopsy case of meningovascular neurosyphilis associated with Fischer's plaques.] [in Japanese] *Brain Nerve.* 2007 Jul;59(7):797-803. [[PubMed](#)] [[CrossRef](#)]
10. Jantzen SU, Ferrea S, Langebner T, Gaebel W, Griese M, Arendt G, et al. Late-stage neurosyphilis presenting with severe neuropsychiatric deficits: diagnosis, therapy, and course of three patients. *J Neurol.* 2012 Apr;259(4): 720-728. [[PubMed](#)] [[CrossRef](#)]
11. Conde-Sendin MA, Hernandez-Fleta JL, Cardenas-Santana MA, Amela-Peris R. [Neurosyphilis: forms of presentation and clinical management.] [in Spanish] *Rev Neurol.* 2002 Aug 16-31;35(4):380-386. [[PubMed](#)]
12. Dhasmana D, Joshi J, Manavi K. Intracerebral and spinal cord syphilitic gummata in an HIV-negative man: a case report. *Sex Transm Dis.* 2013 Aug; 40(8):629-631. [[PubMed](#)] [[CrossRef](#)]
13. Nagappa M, Sinha S, Taly AB, Rao SL, Nagarathna S, Bindu PS, et al. Neurosyphilis: MRI features and their phenotypic correlation in a cohort of 35 patients from a tertiary care university hospital. *Neuroradiology.* 2013 Mar; 55(4):379-388. [[PubMed](#)] [[CrossRef](#)]
14. Dupin N, Farhi D. [Syphilis.] [in French] *Presse Med.* 2013 Apr;42(4 Pt 1):446-453. [[PubMed](#)] [[CrossRef](#)]

Please cite this article as: Dimitrov I, Kaprelyan A, Gentcheva M, Ivanov B, Georgiev R, Avramov T, Entchev Y, Deleva N. LATE NEUROSYPHILIS: TRENDS AND CHALLENGES. *J of IMAB.* 2015 Jul-Sep;21(3):864-867. DOI: <http://dx.doi.org/10.5272/jimab.2015213.864>

Received: 12/05/2015; Published online: 10/09/2015

Address for correspondence:

Ivan Dimitrov, MD, PhD
First Clinic of Neurology, Sveta Marina University Hospital
1, Hristo Smirnenski str., 9010 Varna, Bulgaria
E-mail: indimitrov@mail.bg