



SQUAMOUS CELL CARCINOMA OF THE SKIN: A STUDY OF CLINICOHISTOPATHOLOGICAL CORRELATIONS PREDICTIVE FOR RECURRENCE, METASTASIS AND MORTALITY

Preslav Vasilev¹, Savelina Popovska², Milen Karaivanov², Dobromir Dimitrov³, Ivelina Yordanova¹

1) Department of Dermatology, Venereology and Allergology, University Hospital "Dr Georgi Stranski", Faculty of Medicine, Medical University-Pleven, Bulgaria

2) Department of General and Clinical Pathology, University Hospital "Dr Georgi Stranski", Faculty of Medicine, Medical University-Pleven, Bulgaria

3) Surgical Oncology Department, University Hospital "Dr Georgi Stranski", Faculty of Medicine, Medical University-Pleven, Bulgaria.

ABSTRACT

Introduction: The incidence of Squamous cell carcinoma of the skin (SCCs) increases annually, and this process will likely be continued because of sun exposure, outdoor activities and the aging population.

Objectives: The aim of our study is to analyse clinicohistopathological features, recurrence, metastasis and mortality rates of SCCs in Pleven, Lovech region, Bulgaria.

Methods: We investigated 355 patients with histologically confirmed SCCs for the period 2016 – 2022 and carried out a detailed histopathological analysis of 100 tumors. They were divided into two groups according to their macroscopic diameter: with low risk for recurrence and metastases (<20mm) and high – risk (>20mm). We studied the localisation, histological subtype, tumor cell differentiation, microscopic depth of invasion, perineural and lymphovascular invasion, stromal lymphocyte infiltration.

Results: We revealed that 73,3% of the patients with SCCs reported severe sunburns, and 1,13% of them underwent immunosuppressive treatment. Head and Neck localisation is the most common – 72,7%. We established a mean histological depth of SCCs of 5,92mm, lymphovascular invasion in 7% and perineural invasion in 5% of the cases. We found that tumors with a macroscopic diameter >20mm have a greater depth of invasion in comparison to SCCs with a smaller diameter. We found an incidence of local recurrence of 4,8%, lymph node metastases at 5,1%, far metastases in internal organs at 2,25% and mortality at 1,97%.

Conclusion: Clinicohistopathological features of SCCs with related to recurrence, metastasis and mortality are localisation on the scalp, ears or lips, tumor size >20mm, depth of invasion >6mm, poor tumor cell differentiation, perineural and lymphovascular invasion, low or absent stromal lymphocyte infiltration.

Keywords: histopathology, squamous cell carcinoma, skin cancer, recurrence, metastasis, mortality,

INTRODUCTION

Squamous cell carcinoma of the skin (SCCs) is a malignant tumor which starts its development from the epidermal keratinocytes and is the second most common cancer in the world with continuously increasing incidence rates [1]. The main examples are Australia and the United States, with the highest incidence of SCCs. In Australia, it rates up to 387 per 100 000 person-years, and it is estimated that there will be over 200 000 new cases per year by 2024 [2]. In Europe, the prevalence of the population with skin phototype I and II, combined with frequent UV exposure, may be responsible for the high incidence of SCCs. Additional risk factors include a family history of skin cancer, sun and chemical exposure, and chronic inflammatory skin diseases [3]. Diagnosis, treatment plan and patient outcome are established by detailed histopathological analysis. The different histological presentations of SCCs are related to the patient's prognosis and define the tumor behavior in the future [3, 4]. Most cases are treated successfully by surgical excision with 5-year recurrence-free survival rates greater than 95% and a disease-related death risk of approximately 2% [5]. The high-risk clinicopathological features include primary localisation of SCCs on the scalp, ears or lips, tumor size >20mm, depth of invasion >6mm, poorly differentiated tumors, presence of perineural and lymphovascular invasion, and immunosuppression of the patient [6].

OBJECTIVES

The aim of our study is to establish the age- and sex-related incidence, risk factors, localisation, treatment types, recurrence, metastasis and mortality rates of SCCs in the Pleven, Lovech region in Bulgaria. We also aimed to prepare a detailed histopathological report of high-risk

SCCs and to find an association between the histological features of the tumors and their recurrence.

MATERIALS AND METHODS

We conducted a retrospective and prospective study involving 355 patients with histologically verified SCCs. The cases were selected from the Oncological registry in Pleven, Lovech region, Bulgaria, over a period of six years (2016-2022). The study was conducted through interviews, clinical examination and reviews of patient's medical records. A detailed questionnaire was prepared. It included patient history, sun exposure, localisation and macroscopic diameter, histopathological examination and treatment modalities of the carcinoma. We also performed a histopathological evaluation of 100 invasive SCCs using a comprehensive report. The survey data was processed by IBM SPSS (Statistical Package for Social Sciences) version 20.0.

Ethical aspects

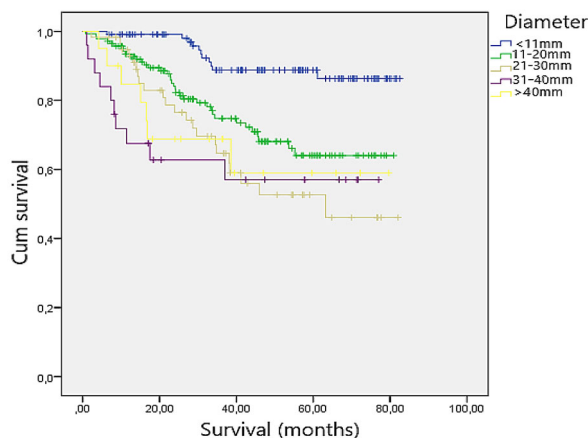
The study was conducted following the national and international requirements for clinical studies, including the preservation of the anonymity of the participants and the non-disclosure of their personal information. Each participant signed an informed consent form before the excision of the suspected lesions during their hospital stay. The study was conducted in accordance with the requirements of the Ethics Committee of the Medical University of Pleven, Bulgaria: approval number ¹ 676/31.05.2022.

RESULTS

Within the study framework, 355 patients suffering from SCCs with an average age of 75,02 years ($\pm 10,74$ SD) were investigated. The male patients were 185 (52,1%) with a mean age of 74,11 years, and the female patients were 170 (47,9%) with an average age of 76,01. Comparing the age and sex of the patients, no statistical differences were registered: $P > 0,05$ (Actual value $P = 0,057$). We analysed sun exposure and immunosuppression as risk factors. Two hundred thirty-nine patients (67,3%) practiced outdoor activities daily, and 260 patients (73,3%) reported severe sunburns in their lives. We found 4 patients (1,13%) undergoing immunosuppressive treatment for concomitant diseases. It is important to emphasise the high incidence of SCCs in the facial region - 206 tumors (58,02 %). We revealed a mean macroscopic diameter of SCCs of 19,86 mm (Standart Deviation - 14,34mm). Statistical analysis found a statistically significant difference between the macroscopic diameter of the lesions in the distinct age groups, tumors with a larger mean macroscopic diameter were found in older patients. $P < 0,05$ (Actual value 0,028). A statistically significant dif-

ference between the macroscopic diameter of the tumors and the overall survival was also noted: $P < 0,05$ (Actual value $p < 0,001$). Correlation analysis between the macroscopic diameter of primary SCCs and overall survival shows that the bigger tumor diameter leads to shorter survival of patients. (Fig. 1)

Fig. 1. Correlation between the macroscopic diameter of primary SCCs and overall survival of the patients.



In the group of studied patients, we found the following clinical variants of SCCs: 302 patients (85,1%) had invasive SCCs, and 53 (14,9%) – “in situ” SCCs. In the group of the “in situ” carcinomas, 1 patient (2,0%) had actinic keratosis, 4 patients (7,8%) were diagnosed with Morbus Bowen and 46 patients (90,2%) suffered from low grade “in situ” SCCs, resembling Keratoacanthoma [7]. In the group of invasive SCCs, 11 patients (3,8%) had superficial SCCs; 129 patients (44,0%) – with ulcerous-infiltrative carcinoma and 153 patients (52,2%) were diagnosed with nodular SCCs. Regarding the treatment, in 303 of the cases (85,4%), the surgical excision leads to full removal of the tumor. In the other 52 patients (14,6%), radiotherapy was applied after surgery. In 17 patients (4,8%), we registered local recurrence. In 18 patients (5,1%), we observed loco-regional lymph node metastasis. In 8 patients (2,25%), we registered far-metastasis in internal organs. We found a statistically significant relationship between the macroscopic diameter of SCCs and their metastasis: $P < 0,05$ (Actual value $P < 0,001$). The analysis of causes of death in the retrospective group of patients showed that a total of 70 patients (19,7%) lost their lives - two patients (0,56%) died from severe Covid-19 infection, 42 patients (11,83%) – from acute vascular accident, 13 patients (3,66%) - because of cardiovascular diseases, 6 patients (1,69%) - from other malignant diseases and 7 patients (1,97%) died because of advanced metastatic SCCs.

In our study, we investigated whether there is a connection between the histopathological features of the SCCs and their macroscopic diameter. We performed a compre-

hensive histopathological evaluation of 100 invasive SCCs, which were divided into 2 groups according to their macroscopic diameter. Group 1 consisted of 50 SCCs with a diameter <20mm and low risk for recurrence and metastasis. Group 2 included 50 tumors with a diameter >20mm and with a high risk for recurrence and metastasis. We studied the localisation, microscopic depth of invasion, tumor cell differentiation, perineural and lymphovascular invasion, lymphocyte stromal reaction of the two groups. In fig. 2 we present the distribution of the tumors according to their localisation in the body. The Head and Neck region is the most commonly affected. In fig.3 we present the facial distribution of the observed SCCs.

Fig. 2. Distribution of SCCs on the body (N-number of patients)

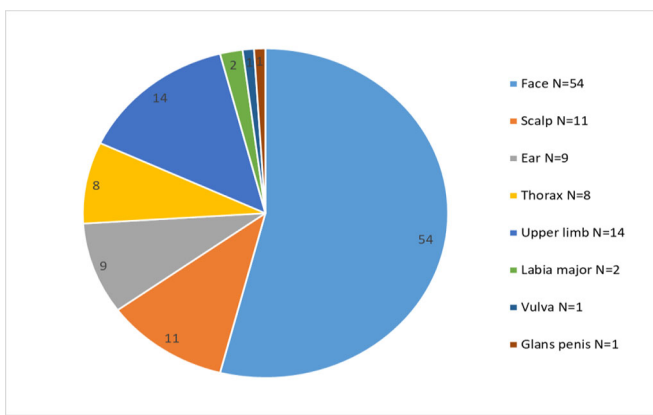
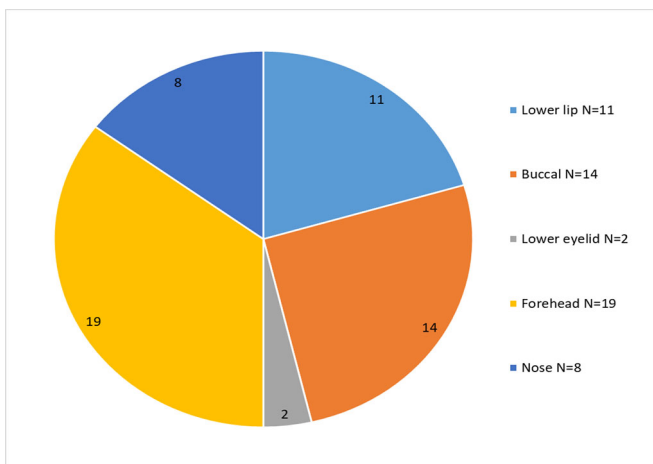


Fig. 3. Distribution of SCCs on the face (N-number of patients)



According to the histopathological subtype, 76 of the tumors were diagnosed as nonspecific (classical) type SCCs, 15 – as Keratoacanthoma-like invasive SCCs, 4 – Acantholytic, 3 – Verrucous, 1 – as clear-cell carcinoma and 1 – as pigmented SCCs (Fig. 4- 9).

Fig. 4. H&E staining: Classical (nonspecific) SCCs (x20)

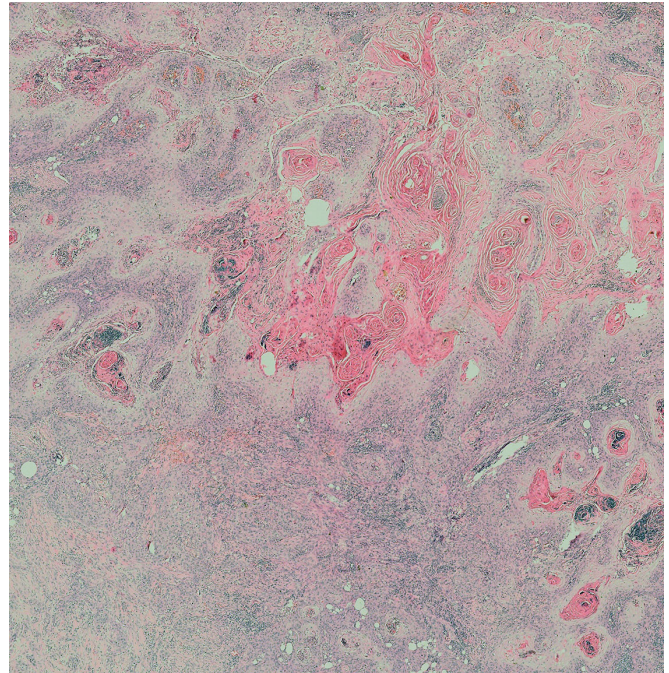


Fig. 5. H&E staining: Keratoacanthoma-like invasive SCCs (x20)

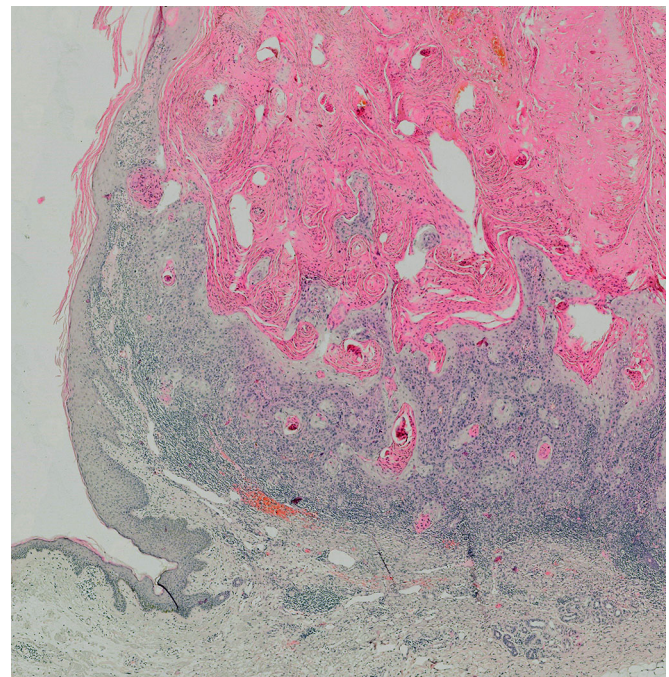


Fig. 6. H&E staining: Acantholytic SCCs (x50)

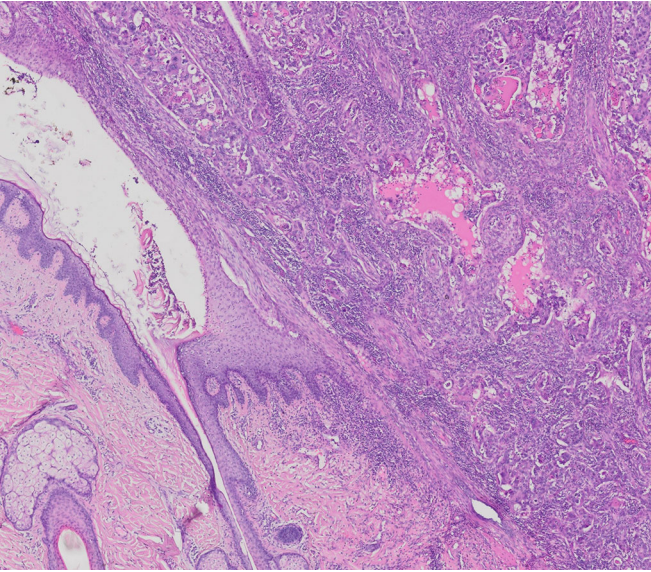


Fig. 9. H&E staining: Pigmented SCCs (x20)

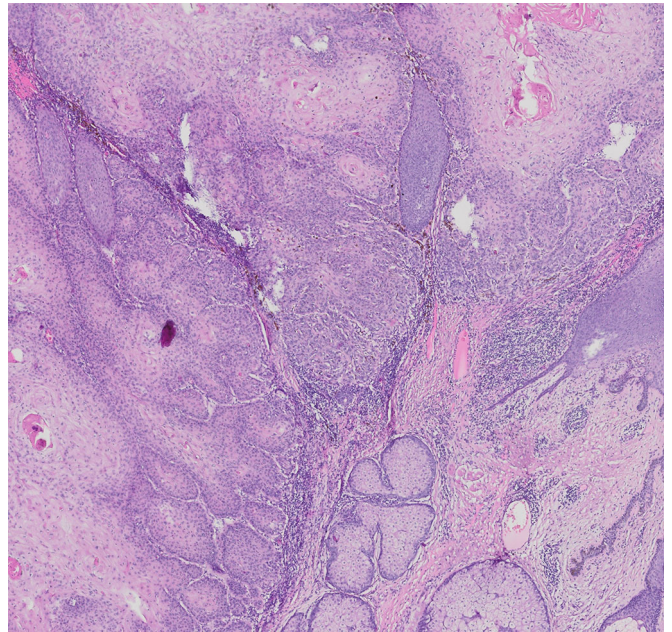


Fig. 7. H&E staining: Verrucous SCCs (x20)

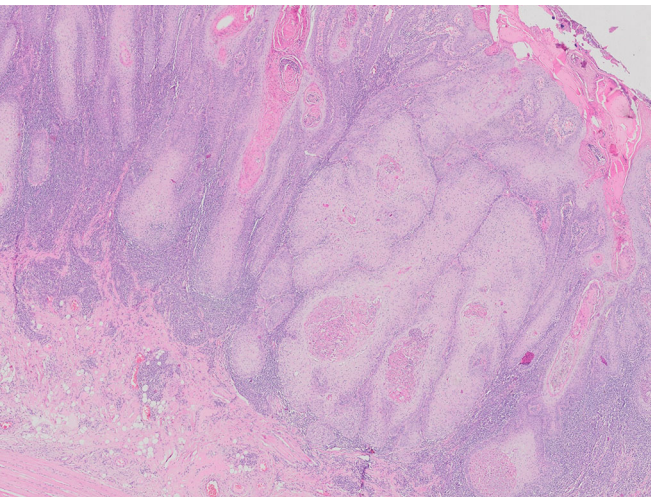
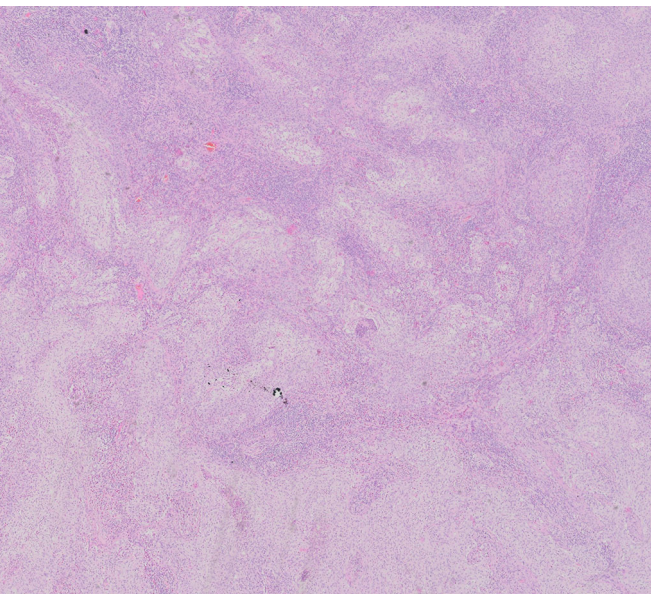


Fig. 8. H&E staining: Clear cell SCCs (x20)



The histomorphological evaluation revealed the predominance of well to moderately-differentiated tumors: 71% were well-differentiated, 19% were moderately differentiated, and 10% were poorly differentiated. Statistical analysis did not find a statistically significant connection between the histological subtypes and the cell differentiation of the tumors $P < 0,05$ (Actual value 0,069). The mean histological depth of the tumors, according to Breslow, was 5,92mm (Standart Deviation – 3,08mm) with a minimal value of 1 mm and maximal value of 18mm. Statistical analysis showed a significant difference between the Breslow depth of invasion in the low- and high-risk group: $P < 0,05$ (Actual value $< 0,001$). Tumors with greater depth of invasion were found in Group 2 (> 20 mm macroscopic diameter). The analysis of the data also showed a statistically significant difference in the Breslow depth of invasion between the classical nonspecific SCCs and the Kerathoacanthoma-like invasive SCCs $P < 0,05$ (Actual value $< 0,001$). Classical nonspecific SCCs had greater depth of invasion. According to the level of invasion, we observed 56 tumors invading the dermis, 36 tumors invading the hypodermis, and 8 tumors invading tissues below the hypodermis (5 – muscles and 3 – perichondrium). We also assessed the lymphovascular and perineural invasion of the tumors: in 7 tumors, we found lymphovascular invasion and in 5 – perineural invasion.

Analysis of the data in the studied groups of invasive SCCs showed that there is a statistically significant connection between the Breslow depth of invasion and the lymphovascular invasion $P < 0,05$ (Actual value 0,001). We did not detect a statistically significant connection between the lymphovascular invasion and the macroscopic diameter of invasive SCCs – $P < 0,05$ (Actual value 0,238), the histological subtype – $P < 0,05$ (Actual value 0,795) and the cell differentiation of the tumors – $P < 0,05$ (Actual value 0,320).

We found a statistically significant connection between the perineural invasion and the depth of invasion of

SCCs $P < 0,05$ (Actual value 0,006). There was no statistically significant connection between the perineural invasion and the macroscopic diameter – $P < 0,05$ (Actual value 0,086), the histological subtype of the SCCs – $P < 0,05$ (Actual value 0,744) and the cell differentiation of the tumors – $P < 0,05$ (Actual value 0,457).

We assessed the stromal lymphocyte infiltration as well. It was high in 68% of the tumors, moderate in 21% of SCCs, low in 10% and absent in 1 tumor. There was no statistically significant connection between the depth of invasion of the tumor and the stromal lymphocyte infiltration $P < 0,05$ (Actual value 0,382). In Group 1 and Group 2, the predominant stromal lymphocyte infiltration was high to moderate. We did not observe a statistically significant difference between the stromal lymphocyte infiltration and the macroscopic diameter in the two groups as well $P < 0,05$ (Actual value 0,224).

According to the histopathological report prepared for the 100 invasive SCCs, 85% of the tumors were fully surgically excised, and in 15% of them, there was the involvement of the adjacent tissues with tumor cells. The analysis of the data showed a statistically significant connection between the full surgical excision and the Breslow depth of invasion of the tumor – $P < 0,05$ (Actual value $< 0,001$), as well as the macroscopic diameter of the invasive SCCs – $P < 0,05$ (Actual value 0,038). The smaller macroscopic diameter of the tumor and depth of invasion lead to more successful surgical treatment. There was no statistically significant connection between the histopathological subtype and the full surgical excision $P < 0,05$ (Actual value 0,325).

DISCUSSION

Our study revealed that patients with extensive sun exposure bear higher risk for SCCs development, like the results reported by Euvrard et al. in Australia [8]. We found that 67,3% of the patients with SCCs practiced outdoor activities daily and 73,3% of them reported having severe sunburns in their lives. According to the data from the literature immunosuppressed patients have a higher risk of developing skin cancer and tend to have a worse prognosis than immunocompetent patients [9]. We found that 1,13% of our patients were undergoing immunosuppressive treatment for concomitant diseases (2 patients – essential thrombocythaemia, 1 – prostate cancer, 1 – breast cancer). Our results show that SCCs is more common in the Head and Neck area (72,7% of the investigated 355 patients), with facial localisation in 58,02 %, similar to the data described by Ramirez et al [10]. According to data from the literature, the risk of SCCs progression is assessed based on data for macroscopic diameter, localisation, histological subtype, cell differentiation, microscopic depth of invasion, infiltration of underlying structures (fascia, muscle, cartilage or bone), presence of perineural and lymphovascular invasion, presence of stromal lymphocyte infiltration [11,12]. A detailed histopathological report is crucial to provide the best management and follow-up of a patient suffering from SCCs. A lot of studies were performed in order to provide information about the histological features of SCCs associated with a higher risk of recurrence, metastasis and mortality. Most of

the results have shown that a tumor diameter greater than 20mm has a higher risk of progression of the disease [10]. Other authors describe 40mm as a tumor diameter with a worse prognosis but state that lesions in the areas of the lip and ear can metastasise even when they are < 20 mm in size. The tumor thickness in mm and in tissue level of invasion are predictors of aggressive disease. Reports show that SCCs with a depth of invasion > 4 mm bring a 45.7% higher risk for recurrence and metastasis. Unlike these tumors, SCCs with a thickness < 2 mm have minimal risk of progression. SCCs with invasion of structures below subcutaneous fat tissue have a strong association with disease-specific mortality [12]. Our results revealed that tumors with macroscopic diameter > 20 mm have a greater depth of invasion in comparison to SCCs with smaller diameter, as described by Mullen et al. [11]. Similar to Clayman et al. we established a mean histological depth of SCCs 5,92mm, bearing a high risk for recurrence and metastasis [12]. We found that classical nonspecific SCCs had greater Breslow depth of invasion than the Keratoacanthoma-like invasive SCCs. The cell differentiation of SCCs has significant effect on the progression risk. Some authors estimated a 37% cure rate for poorly differentiated tumors, 59% - for moderate and 88% - for the well-differentiated SCCs after a median follow-up period of over 2 years [11]. Mendenhall et al. reported perineural and lymphovascular invasion occurring in up to 7% of SCCs and were associated with a higher incidence of recurrence, metastasis and mortality [13]. Similarly, we found lymphovascular invasion in 7% and perineural invasion in 5% of the assessed by us tumors. Our data for local recurrence (4,8%), lymph node metastases (5,1%), far metastases in internal organs (2,25%) and mortality (1,97%) corresponds to the data by Xiang et al. and Karagas et al. – local recurrence rate of 5,4% and mortality rate of 1.5% - 2% in the USA, reaching up to 4% in other countries [14, 15].

CONCLUSIONS

With the rising incidence of SCCs, more focus should be placed on the higher risk tumors. Clinicians should have a high suspicion index for high-risk immunosuppressed patients, and for SCCs clinicohistopathological features such as: primary localisation on scalp, ears or lips, tumor size > 20 mm, depth of invasion > 6 mm, poorly differentiated tumors, presence of perineural and lymphovascular invasion, low or absent stromal lymphocyte infiltration. Our study presents original data on the epidemiology, clinical and histopathological variants of SCCs, main risk factors for local recurrence, progression of the disease and mortality. This is the first study of SCCs with statistical analysis of large population cohort in Bulgaria.

Acknowledgement:

This study was conducted with financial support from Medical University – Pleven, Bulgaria within the Project 7/ 2022.

The statistical analysis was performed by Prof. Todor Kundurzhiev, PhD, Biostatistics and Medical Informatics, Department of Occupational Medicine, Faculty of Public Health, Medical University, Sofia, Bulgaria

REFERENCES:

1. Karia PS, Han J, Schmults CD. Cutaneous squamous cell carcinoma: estimated incidence of disease, nodal metastasis, and deaths from disease in the United States, 2012. *J Am Acad Dermatol*. 2013 Jun;68(6):957-66. [PubMed]
2. Bray F, Ferlay J, Soerjomataram I, Siegel RL, Torre LA, Jemal A. Global cancer statistics 2018: GLOBOCAN estimates of incidence and mortality worldwide for 36 cancers in 185 countries. *CA Cancer J Clin*. 2018 Nov;68(6):394-424. [PubMed]
3. Alam M, Ratner D. Cutaneous squamous-cell carcinoma. *N Engl J Med*. 2001 Mar 29;344(13):975-83. [PubMed]
4. Brantsch KD, Meisner C, Schönfisch B, Trilling B, Wehner-Caroli J, Röcken M, et al. Analysis of risk factors determining prognosis of cutaneous squamous-cell carcinoma: a prospective study. *Lancet Oncol*. 2008 Aug;9(8):713-20. [PubMed]
5. Amoils M, Lee CS, Sunwoo J, Aasi SZ, Hara W, Kim J, et al. Node-positive cutaneous squamous cell carcinoma of the head and neck: Survival, high-risk features, and adjuvant chemoradiotherapy outcomes. *Head Neck*. 2017 May;39(5):881-885. [PubMed]
6. Kyrgidis A, Tzellos TG, Kechagias N, Patrikidou A, Xirou P, Kitikidou K, et al. Cutaneous squamous cell carcinoma (SCC) of the head and neck: risk factors of overall and recurrence-free survival. *Eur J Cancer*. 2010 Jun;46(9):1563-72. [PubMed]
7. Tisack A, Fotouhi A, Fidai C, Friedman BJ, Ozog D, Veenstra J. A clinical and biological review of keratoacanthoma. *Br J Dermatol*. 2021 Sep;185(3):487-498. [PubMed]
8. Euvrard S, Kanitakis J, Decullier E, Butnaru AC, Lefrançois N, Boissonnat P, et al. Subsequent skin cancers in kidney and heart transplant recipients after the first squamous cell carcinoma. *Transplantation*. 2006 Apr 27;81(8):1093-100. [PubMed]
9. Smith KJ, Hamza S, Skelton H. Histologic features in primary cutaneous squamous cell carcinomas in immunocompromised patients focusing on organ transplant patients. *Dermatol Surg*. 2004 Apr;30(4 Pt 2):634-41. [PubMed]
10. Ramirez CC, Federman DG, Kirsner RS. Skin cancer as an occupational disease: the effect of ultraviolet and other forms of radiation. *Int J Dermatol*. 2005 Feb;44(2):95-100. [PubMed]
11. Mullen JT, Feng L, Xing Y, Mansfield PF, Gershenwald JE, Lee JE et al. Invasive squamous cell carcinoma of the skin: defining a high-risk group. *Ann Surg Oncol*. 2006 Jul;13(7):902-9. [PubMed]
12. Clayman GL, Lee JJ, Holsinger FC, Zhou X, Duvic M, El-Naggar AK, et al. Mortality risk from squamous cell skin cancer. *J Clin Oncol*. 2005 Feb 1;23(4):759-65. [PubMed]
13. Mendenhall WM, Amdur RJ, Hinerman RW, Werning JW, Malyapa RS, Villaret DB, et al. Skin cancer of the head and neck with perineural invasion. *Am J Clin Oncol*. 2007 Feb;30(1):93-6. [PubMed]
14. Xiang F, Lucas R, Hales S, Neale R. Incidence of nonmelanoma skin cancer in relation to ambient UV radiation in white populations, 1978-2012: empirical relationships. *JAMA Dermatol*. 2014 Oct;150(10):1063-71. [PubMed]
15. Karagas MR, Greenberg ER, Spencer SK, Stukel TA, Mott LA. Increase in incidence rates of basal cell and squamous cell skin cancer in New Hampshire, USA. New Hampshire Skin Cancer Study Group. *Int J Cancer*. 1999 May 17;81(4):555-9. [PubMed]

Please cite this article as: Vasilev P, Popovska S, Karaivanov M, Dimitrov D, Yordanova I. Squamous cell carcinoma of the skin: a study of clinicohistopathological correlations predictive for recurrence, metastasis and mortality. *J of IMAB*. 2023 Oct-Dec;29(4):5139-5144. [Crossref - <https://doi.org/10.5272/jimab.2023294.5139>]

Received: 27/04/2023; Published online: 02/10/2023



Address for correspondence:

Preslav Plamenov Vasilev
Department of Dermatology and Venereology Faculty of Medicine, Medical University-Pleven
91, General Vladimir Vazov str. 5800, Pleven, Bulgaria
E-mail: preslav.vasilev@abv.bg,