

REPAIR OF PERIAPICAL STRUCTURES IN APICAL PERIODONTITIS USING TWO STEP METHOD

Angela Gusiyska

*Department of Operative Dentistry and Endodontics
Faculty of Dental medicine, Medical University, Sofia.*

SUMMARY

INTRODUCTION: Apical periodontitis is a result of infection in root canal system and manifestation of the host defense response. The aim of this study is to compare radiographically regeneration of periapical lesions in roots with infected root canals obturated with calcium hydroxide $\text{Ca}(\text{OH})_2$ / ApexCal - Ivoclar Vivadent/ as intracanal medication in two steps. Phenols and aldehydes, chlorophenol camphor thymol and iodoform paste, formocresol and tricresol formalin are sometimes also recommended for this indication. Calcium hydroxide is an effective, biocompatible substance that has been widely studied in scientific research. It is regarded as the material of choice for temporary disinfectant dressings.

METHODOLOGY: Standardized preoperative periapical radiographs were taken of 22 tooth of 22 patients / 9 female and 13 male /. All roots were then aseptically instrumented to ISO. 12 roots were aseptically instrumented to ISO size 45, 6 roots were aseptically instrumented to ISO size 50 and the remaining roots were instrumented to ISO size 60 in apical control zone. Roots were irrigated with 10 cc NaOCl 5,25% and 17 % EDTA solution , and then irrigated with 10 cc saline. After saline irrigation ApexCal was placed with a lentulo in the canal for 10 days. Then roots were definitely obturated with Apexit Plus

RESULTS: Antibacterial properties of temporary dressings in treatment of apical periodontitis have been the subject of much controversy. Radiographically and clinically treatment would be statistically superior to one-step treatment. Regeneration of periapical structures after 3 , 6 and 12 months is significant for healing process.

DISCUSSION: Accurate knowledge of root anatomy is an important to radiographic resources, tactile sense and operator's clinical experience, thus contributing to the success of endodontic treatment. Incomplete disinfection of the root canal system is frequently a cause of failure of endodontic treatment.

CONCLUSIONS: Clinical study of this 22 cases with periapical lesions appears to be related with use of ApexCal, $\text{Ca}(\text{OH})_2$ antibacterial dressing in root canal system. The antibacterial effect of calcium hydroxide is

based on the material's capacity to release hydroxide ions in an aqueous environment. The bactericidal effect arises from the destruction of cell membranes and the denaturalization of structural proteins and enzymes.

Key words: Apical periodontitis, periapical structures, regeneration, $\text{Ca}(\text{OH})_2$.

INTRODUCTION

The periodontium is an unusually complex tissue comprised of two hard /cementum and bone/ and two soft/ gingiva and periodontal ligament/ tissues. The biochemistry and cell biology of the normal periodontium as well as the pathological changes associated with the inflammatory periodontal diseases are the aim of many research studies. The ultimate aim of endodontic treatment is to encourage the healing of apical periodontitis or to prevent it from occurring if it was not present prior to treatment. Apical periodontitis is a general term used to describe an inflammatory response to irritation caused by the contents of a root canal system and it has several distinct forms.

This clinical study presents the procedures that must be considered for regeneration of periapical structures after nonsurgical endodontic treatment. Nonsurgical root canal therapy was performed and lesion healing was confirmed radiographically after 3,6 and 12 months

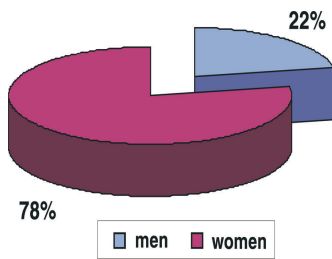
The presence of several distinct types of bacteria in the necrotic dental pulp was demonstrated more than a century ago.(1)

For elimination or maximum reduction of microorganisms in the root canal system, the professional should associate debridment using endodontic files with efficient irrigating solution and intracanal medication. Moreover, patency and enlargement of the canals in case of necrotic teeth with periapical lesions will help eliminating microorganisms from the apical foramen, thus preventing the inflammatory process to perpetuate.

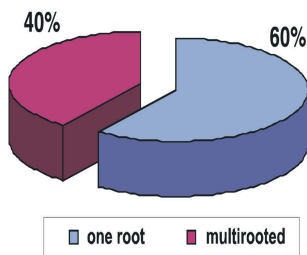
Calcium hydroxide dressings were selected because they reportedly provide excellent clinical and laboratorial results . Calcium hydroxide was associated to an aqueous vehicle to allow rapid release of Ca and OH ions .

METHODOLOGY

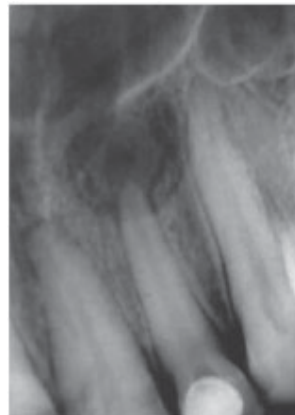
Standardized preoperative and postoperative periapical radiographs by right-angle technique, were taken of 36 teeth of 30 patients /21 molars, 5 premolars and 10 incisors/. (pic.1, 2, 3)



Pic. 1.



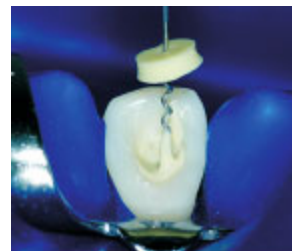Pic. 2.



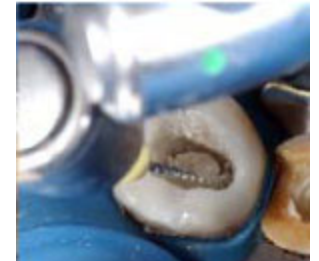Pic. 3.

24 roots were aseptically instrumented to ISO size 45, 9 roots were aseptically instrumented to ISO size 50 and the remaining roots were instrumented to ISO size 60 in apical control zone.

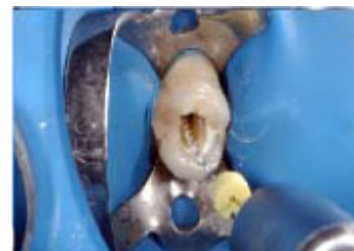Roots were irrigated with 10 cc NaOCl 5.25% and 17 % EDTA solution , and then irrigated with 10 cc saline. After saline irrigation calcium hydroxide /ApexCal, Ivoclar Vivadent/ was placed with a lentulo in the canals for 10 days. (pic. 8, 9, 10)



Pic. 8.

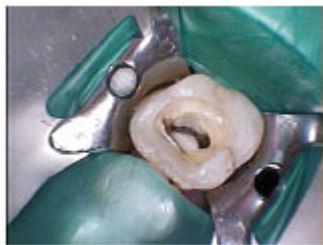

Pic. 9.

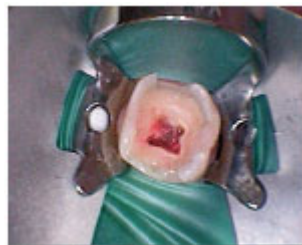

Pic. 10.

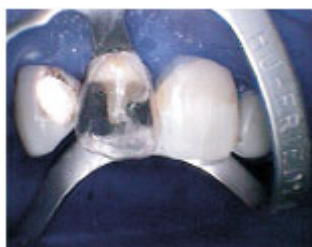All procedures were carried out under Rubber dam isolation. Thereby were eliminate reinfection of endodontic interface. (pic. 4, 5, 6, 7)



Pic. 4



Pic. 5



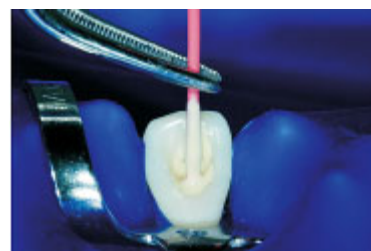Pic. 6



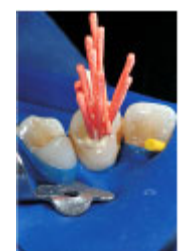Pic. 7

- How does calcium hydroxide work?
- Release of calcium and hydroxyl ions
 - Long-lasting effect
 - Destructs the cell membrane of bacteria
 - Denaturates protein
 - Damages the DNA molecule
 - Disintegrates lipopolysaccharides
 - Promotes the dissolution of necrotic tissue
 - Stimulates bone regeneration

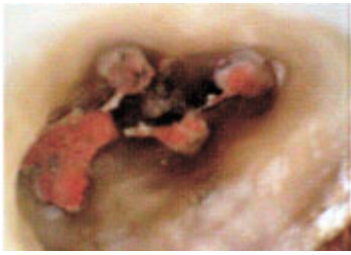After the chemomechanical preparation the roots were definitely obturated with gutta-percha and Apexit Plus/ Ivoclar Vivadent/ as a sealer using the lateral condensation technique. (pic. 11, 12, 13)



Pic. 11. Pic. 12.

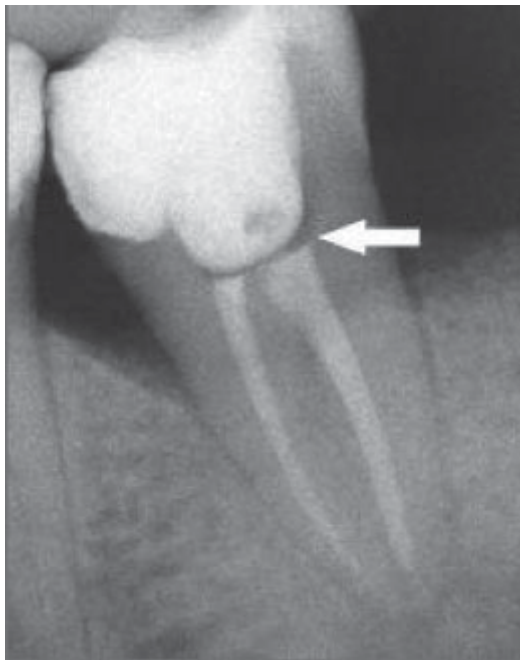


The canals were instrumented with rotating NiTi-instruments /Liberator, Miltex/. The apical control zone of



Pic. 13.

Apexit Plus is a two-component material, which sets by complex formation. For this complex formation the three components calcium hydroxide, salicylate and water are needed and the following reaction is postulated: traces of water cause small quantities of calcium hydroxide to dissolve releasing hydroxide ions that subsequently react with acidic groups of the salicylate. Free calcium ions react to form a chelate complex. The orifices were sealed with CoroSeal /Ivoclar Vivadent/ (pic. 14), using selfetch adhesive and definitive restorations were then placed.

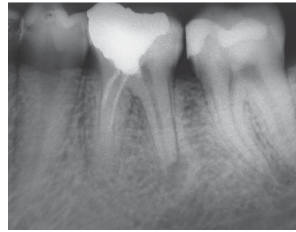


Pic. 14.

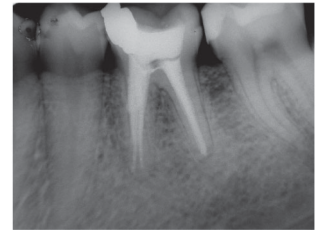RESULTS

Antibacterial properties of temporary dressings in treatment of apical periodontitis have been the subject of much controversy. Radiographically and clinically treatment would be statistically superior to two-step treatment. Regeneration of periapical structures after 3, 6 and 12 months is significant for healing process.

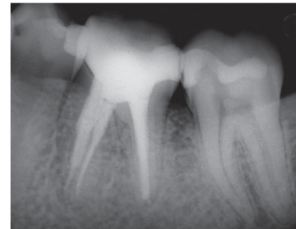
CLINICAL CASE 1



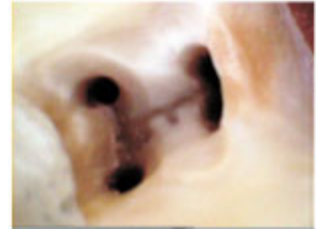Pic. 15. pre-op status 36



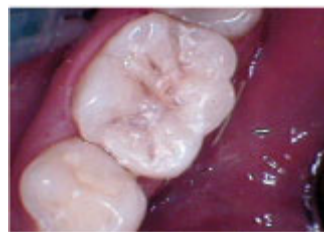Pic. 16. after 6 months 36



Pic. 17. after 12 months 36

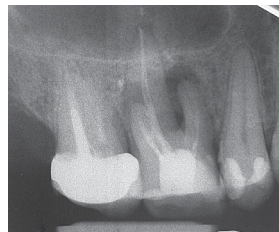

Pic. 18. prepared orifices

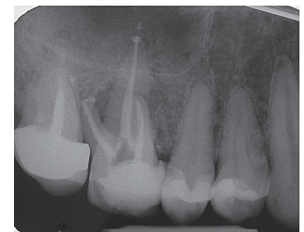

Pic. 19. definitive restoration 36

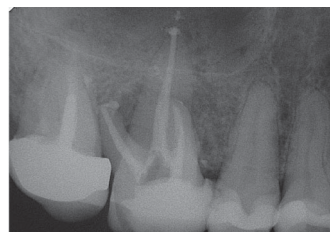
CLINICAL CASE 2



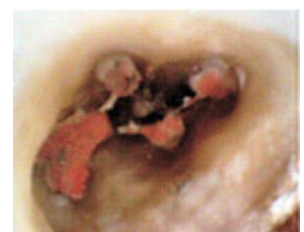Pic. 20. pre-op status 26



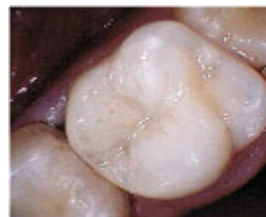Pic. 21. post-op status 26



Pic. 22. after 6 months 26



Pic.23. prepared orifices



Pic.24. definitive restoration 26

DISCUSSION

Accurate knowledge of root anatomy is an important factor to radiographic resources, tactile sense and operator's clinical experience, thus contributing to the success of endodontic treatment. Incomplete disinfection of the root canal system is frequently a cause of failure of endodontic treatment (2).

Root canal cleaning occurs during chemomechanical preparation, which eliminates bacteria, their sub-products, degenerated pulp and contaminated dentine, resulting in a surgical space for adequate sealing. This process occurs by the mechanical action of the instruments in the root canal associated to the chemical action of the irrigating solutions and the irrigation-aspiration process.

Root canal preparation has clear and well-defined goals (3):

- eliminate all pulp tissue
- necrotic debris
- to enlarge and shape the canal space
- make smooth interface to accept a three-dimensional filling.

The difficulty in endodontics are the understanding of the relationships between the presence of smear layer and the success of root canal treatment.

The mechanism of calcium hydroxide in this context is not fully understood.

Relatively the slow solubility of calcium hydroxide is of clinical importance, as it is responsible for the release of OH⁻ ions and the slowly resorption of the material. The main effect of calcium oxide is the ionic dissociation and release of Ca²⁺ and OH⁻.

During root canal preparation, dentin chips produced by instrumentation and fragments of apical pulp tissue tend to be compacted into the foramen, which may cause apical blockage and interfere with the working length. The repeated

penetration of the apical foramen with a file of adequate size during instrumentation prevents the accumulation of debris in this area leaving the foramen unblocked, i.e., patent. This concept has been defined as apical foramen patency in use of Ca(OH)₂ (4,5).

It is very important to know that once damaged the periodontal ligament has a limited capacity of regeneration and this is a challenge of root canal therapy. Repair of periodontal ligament appears to involve progenitor cells, present in the periodontal ligament, capable of forming fibroblasts, osteoblasts and cementoblasts (6). These cells appear clustered near blood vessels in the periodontal ligament and have characteristics of progenitor cells (7, 8).

Moreover, progenitor cells in endosteal spaces potentially migrate from the bone to periodontal ligament to form tissues of the periodontium (9).

CONCLUSIONS

Even after mechanical instrumentation and irrigation with antimicrobial treatment, bacteria can survive. Placement of intracanal medicaments has therefore been recommended. Clinical study of this 22 cases with periapical lesions appears to be related with use of ApexCal, Ca(OH)₂ antibacterial dressing in root canal system. The antibacterial effect of calcium hydroxide is based on the material's capacity to release hydroxide ions in an aqueous environment. Ca(OH)₂ increases the pH not only inside root canals but also in surrounding dentine and periradicular tissues.

It is probably that the mesenchymal stem cells with characteristics of progenitor cells in periodontal ligament are involved in the repair and regeneration of apical zone after two-step endodontic treatment with ApexCal and Apexit Plus filling.

These mechanisms are unknown but that is the question of future.

REFERENCES

1. Miller, 1890. The micro-organisms of the human mouth. Philadelphia: White Dental Mfg. Co.
2. Sundqvist G, Figdor D, Persson S, Sjogren U. Microbiologic analysis of teeth with failed endodontic treatment and the outcome of conservative re-treatment. *Oral Surg Oral Med Oral Pathol* 2003;85:86-93.
3. Schilder H., The value of culturing in endodontic treatment. *Dent Clin North Am.* 1966 Mar;:127-38.
4. Caliskan MK, Sem BH. Endodontic treatment of teeth with apical periodontitis using calcium hydroxide: a long-term study. *Endod Dent Traumatol* 1996;12:215-221.
5. Siqueira Jr. JF, Lopes HP. Mechanisms of antimicrobial activity of calcium hydroxide: a critical review. *Int Endod J* 2001; 34:361-369.
6. Melcher AH, 1976. On the repair potential of periodontal tissues. *J Periodontol* 47:256-260
7. Gould TR, et al 1980. Migration and division of progenitor cell populations in periodontal ligament after wounding. *J Periodontal Res* 15:20-42
8. McCulloch CA, 1985. Progenitor cell populations in the periodontal ligament of mice. *Anat Rec* 211:258-262
9. Kramer PR, et al 2004. Mesenchymal Stem Cells Acquire Characteristics of Cells In the Periodontal Ligament in vitro. *J Dent Res* 83 (1):27-34, 2004

Address for correspondence:

Angela Gusiyska

Department of Operative Dentistry and Endodontics,
Faculty of Dental Medicine, Medical University - Sofia
1, Georgi Sofiiski str., 1431 Sofia, Bulgaria; e-mail: gusiyska@yahoo.com